

Altered gesture imitation and brain anatomy in adult Prader Willi syndrome patients

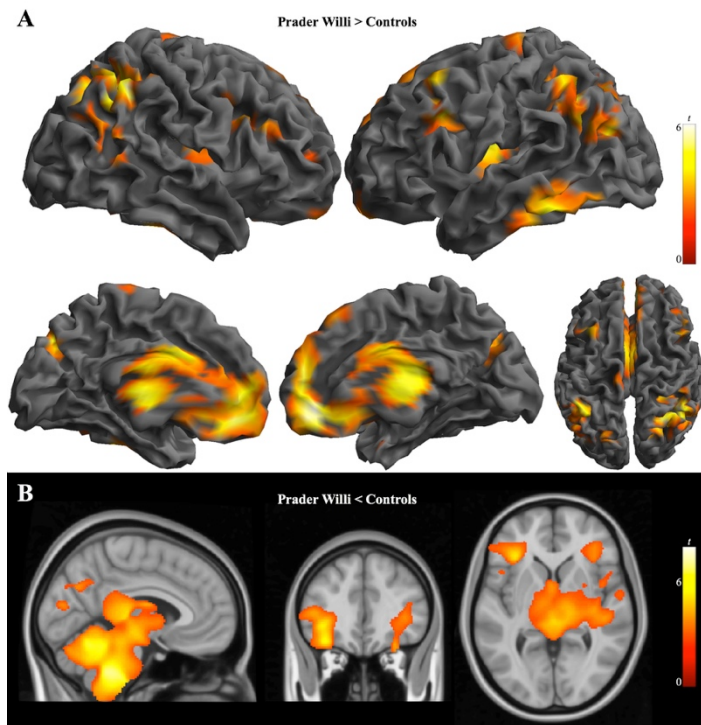
(Caixàs et al.)

Supplementary Material

Supplementary Figure 1. Differences in regional brain volumes between Prader Willi syndrome patients and BMI-matched controls.

Supplementary Table 1. Regional gray and white matter volume differences between PWS patients and healthy controls.

Supplementary Table 2. Regional gray and white matter volume differences between PWS patients and BMI-matched controls.



Supplementary Figure 1. Regional gray and white matter volume change in patients with PWS as compared to BMI-matched control subjects superimposed on 3D renderings (right and left lateral, medial and top views) in (A) and orthogonal displays (sagittal, coronal, and axial views) in (B). (A) Relative gray matter volume increases. (B) Relative white matter volume reductions. Color bar represents t value. Right side of the figure corresponds to the right hemisphere for coronal and axial views.

Supplementary Table 1. Regional gray and white matter volume differences demonstrated by patients with PWS compared to healthy controls.

Brain Tissue	<i>Cluster size, ml</i>	<i>x y z</i>	<i>t</i>
Gray matter			
<i>Prader Willi > Controls</i>			
Thalamus/Basal ganglia/sgACC	114.7	3 -24 6	6.6
Postcentral/Precentral gyrus	63.3	27 -35 68	5.2
Superior Parietal cortex/Angular gyrus	5.2	59 -60 27	4.1
Dorsolateral Prefrontal cortex	2.3	-32 15 53	3.6
Inferior frontal gyrus, pars opercularis	4.4	-42 20 18	3.4
<i>Prader Willi < Controls</i>			
Caudate nucleus	2.4	-23 6 21	3.9
Cerebellum	3.0	-21 -57 -53	3.8
White matter			
<i>Prader Willi > Controls</i>			
Cerebellum	3.5	6 -78 -45	4.6
Putamen/external capsule	3.2	38 11 -11	3.9
<i>Prader Willi < Controls</i>			
Brainstem	18.0	11 -38 -53	6.8
R Frontal operculum	66.9	48 21 -2	6.2
L Inferior Longitudinal fasciculus	*	-49 3 -28	4.2
R Inferior Longitudinal fasciculus	*	42 9 -22	4.0
L Frontal operculum	7.4	-38 38 -2	4.2
Thalamus/Cerebellum	40.9	-3 -24 6	5.2
Corpus callosum	*	-2 -30 18	4.8
Cerebellum	*	2 -47 -22	4.1
L Inferior Occipital regions	2.4	-38 -80 9	4.8
L Postcentral gyrus	9.2	-54 -24 54	4.7
R Postcentral gyrus	10.4	21 -36 75	4.7
L Superior occipital/Angular gyrus region	8.6	-27 -74 33	4.1

x y z, coordinates (mm) given in Montreal Neurological Institute (MNI) stereotactic space.

Statistics at corrected threshold $P_{FWE} < 0.05$ estimated using Monte Carlo simulations.

PWS, Prader Willi syndrome. sgACC, subgenual anterior cingulate cortex. R, right. L, left.

*indicates same cluster.

Supplementary Table 2. Regional gray and white matter volume differences demonstrated by patients with PWS compared to BMI-matched controls.

Brain Tissue	<i>Cluster size, ml</i>	<i>x y z</i>	<i>t</i>
Gray matter			
<i>Prader Willi > Controls</i>			
Thalamus/Basal ganglia/sgACC	151.1	2 -47 -9	6.0
Superior Parietal cortex/Angular gyrus	29.5	45 -51 45	5.9
Inferior Temporal cortex	12.3	-66 -45 -23	5.2
Dorsolateral Prefrontal cortex	4.2	-33 17 48	4.4
Precentral gyrus	2.0	-14 -24 72	3.3
<i>Prader Willi < Controls</i>			
L Caudate nucleus	6.1	-18 12 18	5.2
R Caudate nucleus	5.1	24 13 15	4.7
Hippocampus	2.4	30 -30 -3	4.7
Temporal pole	1.9	52 16 -24	3.2
White matter			
<i>Prader Willi < Controls</i>			
Brainstem	224.5	9 -41 -48	7.9
Cerebellum	*	4 -60 -22	6.1
Thalamus	*	-3 -24 6	4.2
Corpus callosum	*	-2 -30 18	4.0
R Frontal operculum	*	36 31 3	3.6
R Inferior Longitudinal fasciculus	*	39 7 -24	3.3
L Frontal operculum	38.4	-36 30 -3	6.0
L Inferior Longitudinal fasciculus	*	-45 8 -30	3.8
R Precentral gyrus	4.6	61 3 15	4.7

x y z, coordinates (mm) given in Montreal Neurological Institute (MNI) stereotactic space. Statistics at corrected threshold $P_{FWE} < 0.05$ estimated using Monte Carlo simulations. PWS, Prader Willi syndrome. sgACC, subgenual anterior cingulate cortex. R, right. L, left. *indicates same cluster.