

**Supplementary Figure 1:** Exemplary fox lungs macroscopically scored from 0-3 according to macroscopic pathological changes. Score 0 (a): healthy lung without pathological changes; score 1 (b): mild changes (discoloration (black arrows)); score 2 (c): moderate pathologies (discoloration (black arrow), increased tissue density with nodules and discoloration (green arrows)); score 3 (d): severe pathologies (increased tissue consistency, nodules and discoloration (green arrows), adhesion with pericardium and mediastinum (blue arrow)).

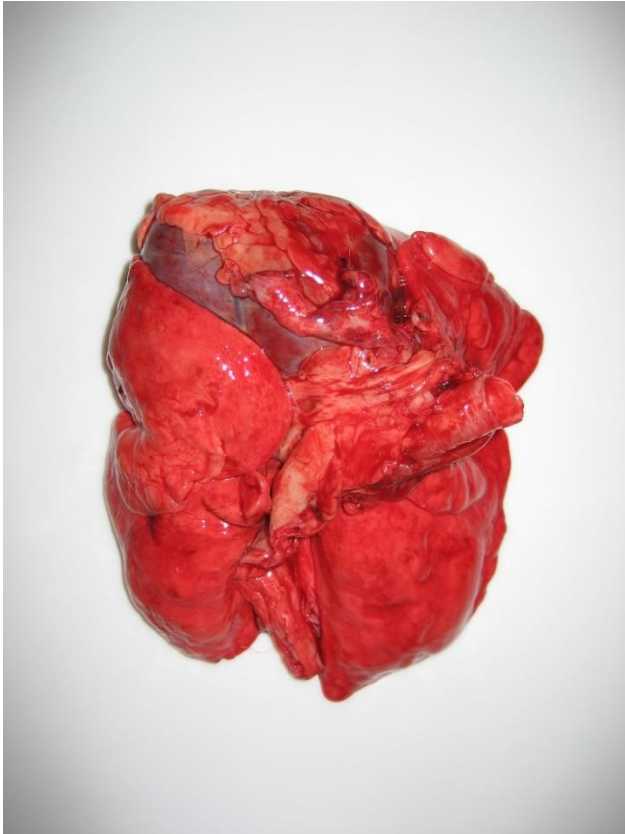


Fig. S1a

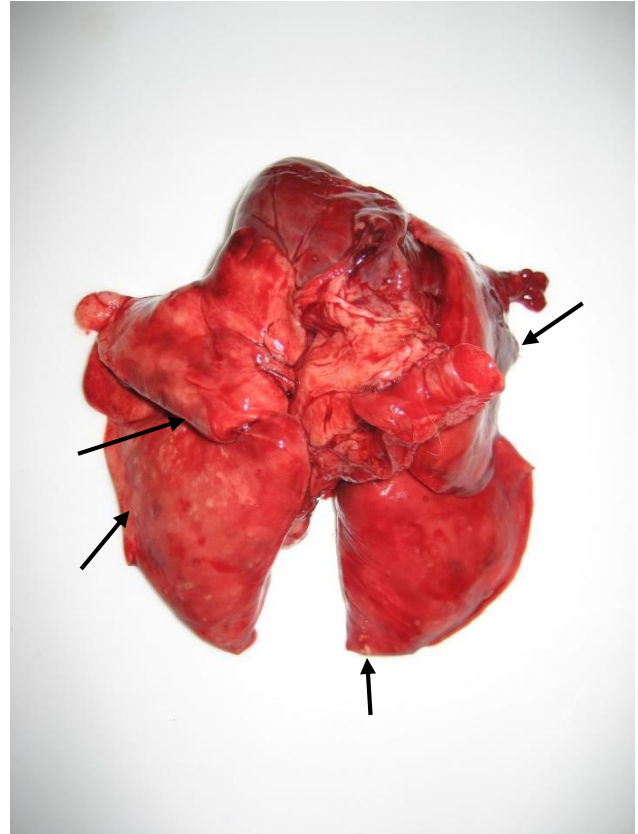


Fig. S1b

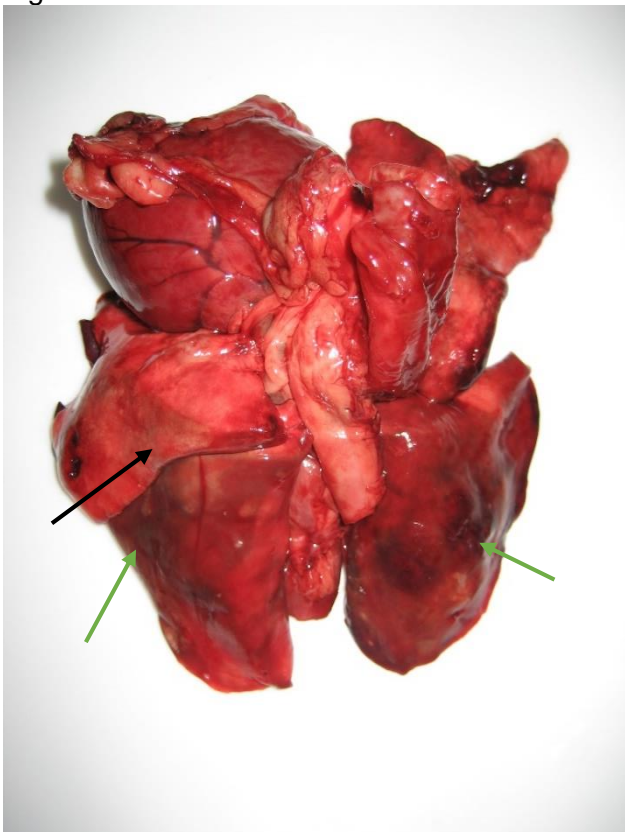

Fig. S1c

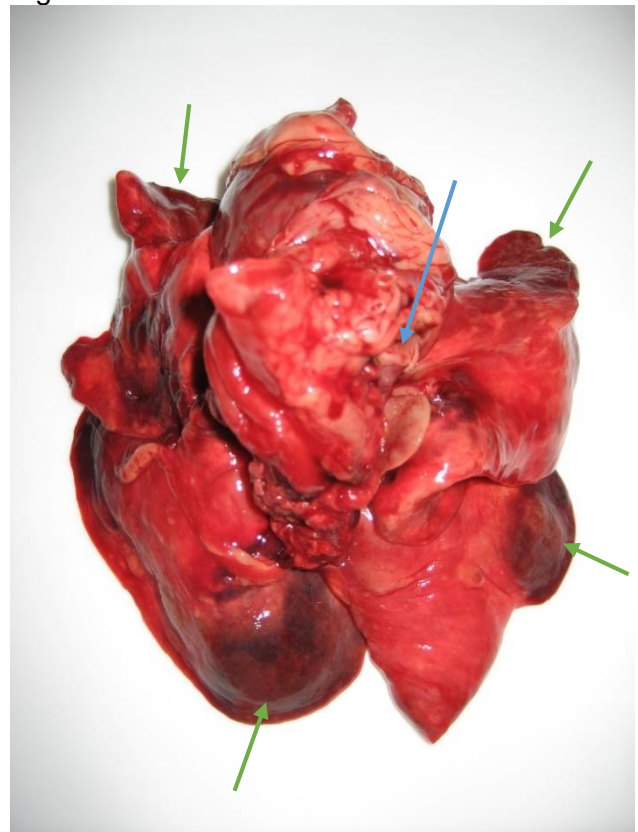


Fig. S1d