BJPsych
The British Journal of Psychiatry
1–3. doi: 10.1192/bjp.bp.112.108464

Online supplement

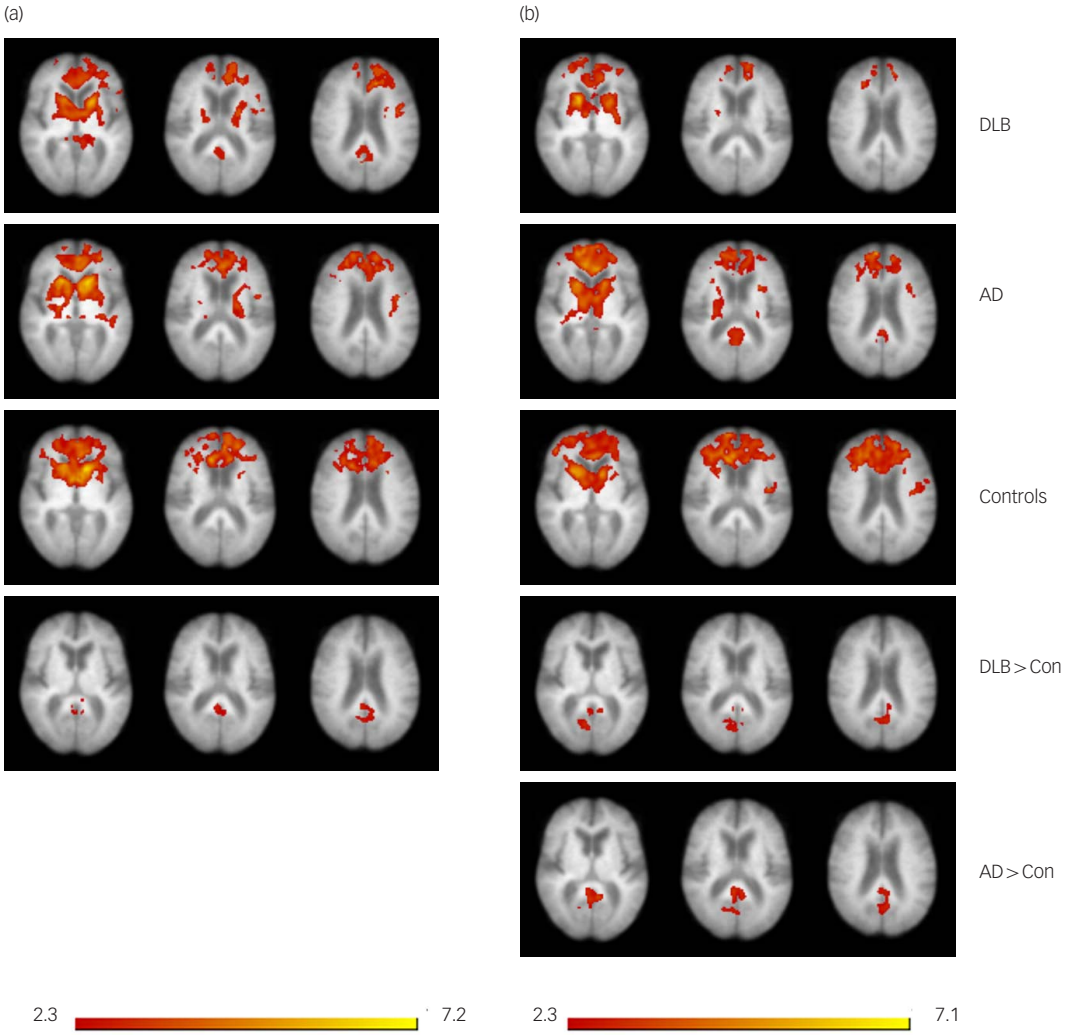

Fig. DS1 Functional connectivity maps of group means and group differences with the head of the (a) left and (b) right caudate nucleus.

Axial view of brain regions in radiological presentation showing significant connectivity ($Z > 2.3$, $P < 0.05$), overlaid on the mean structural scan of all study participants.
DLB, dementia with Lewy bodies; AD, Alzheimer's disease; Con, controls.

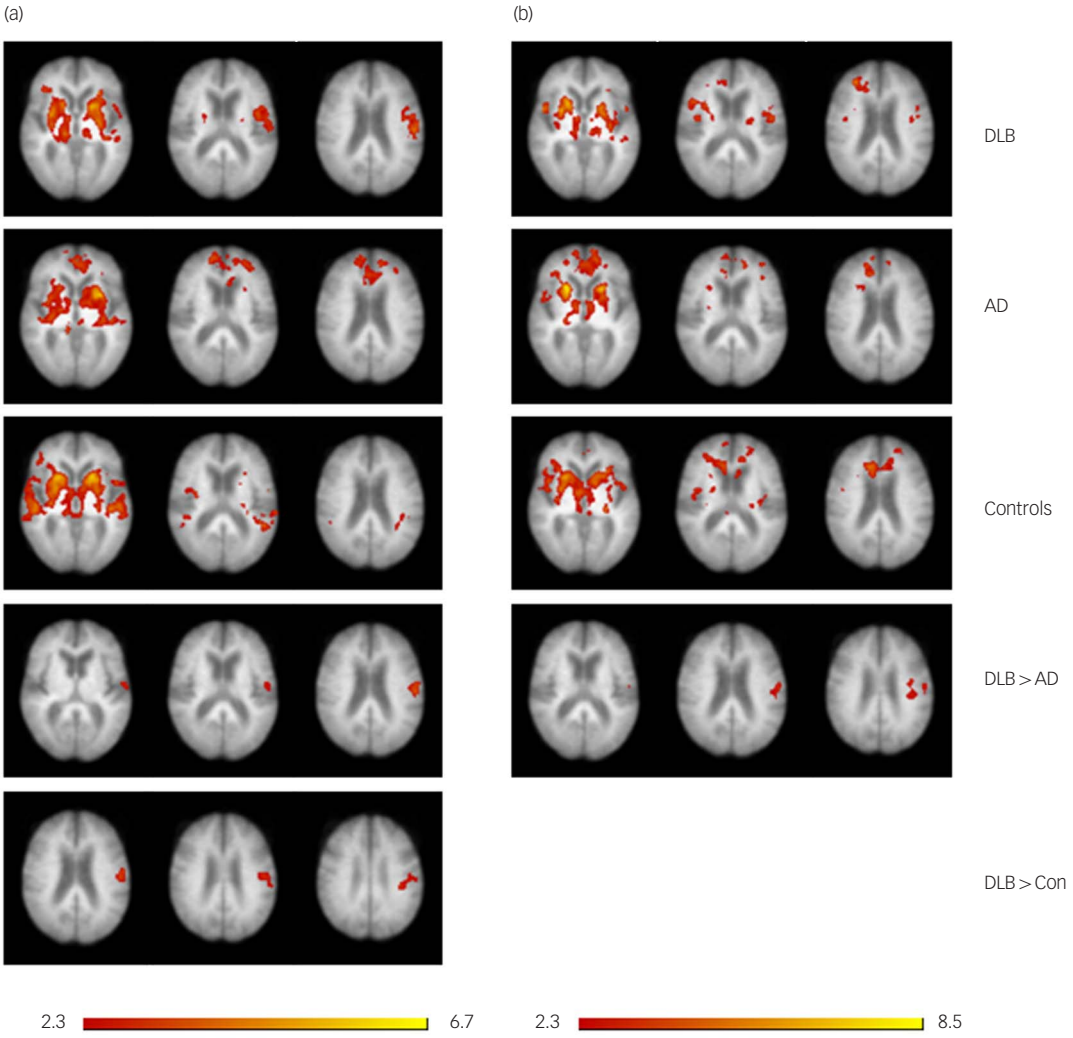

Fig. DS2 Functional connectivity maps of group means and group differences with the (a) left and (b) right putamen.

Axial view of brain regions in radiological presentation showing significant connectivity ($Z > 2.3$, $P < 0.05$), overlaid on the mean structural scan of all study participants. DLB, dementia with Lewy bodies; AD, Alzheimer's disease; Con, controls.

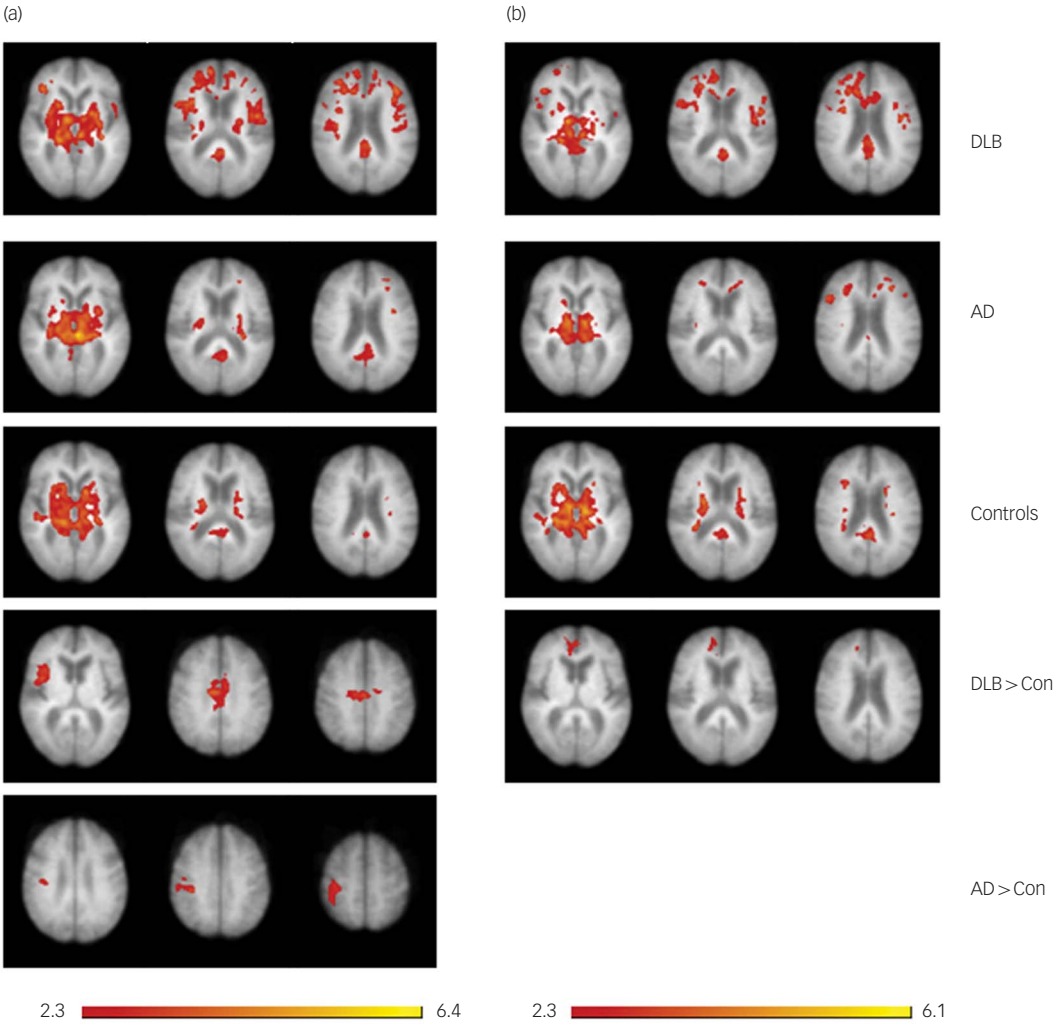

Fig. DS3 Functional connectivity maps of group means and group differences with the (a) left and (b) right thalamus (mediodorsal nucleus).

Axial view of brain regions in radiological presentation showing significant connectivity ($Z > 2.3$, $P < 0.05$), overlaid on the mean structural scan of all study participants.
DLB, dementia with Lewy bodies; AD, Alzheimer's disease; Con, controls.