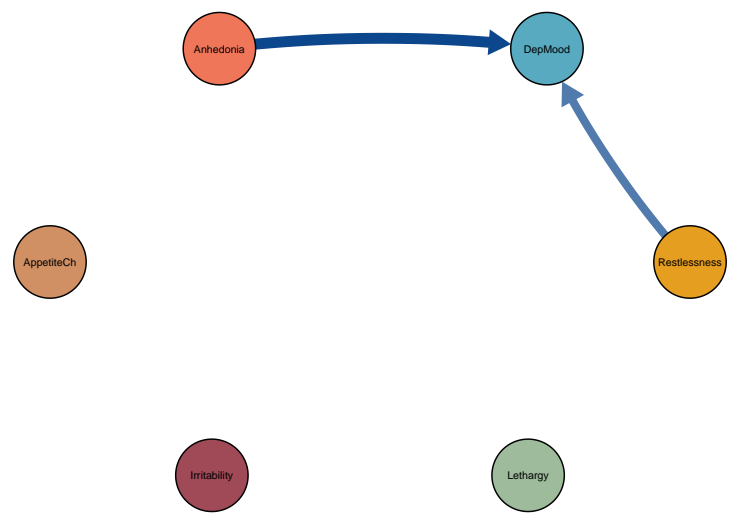
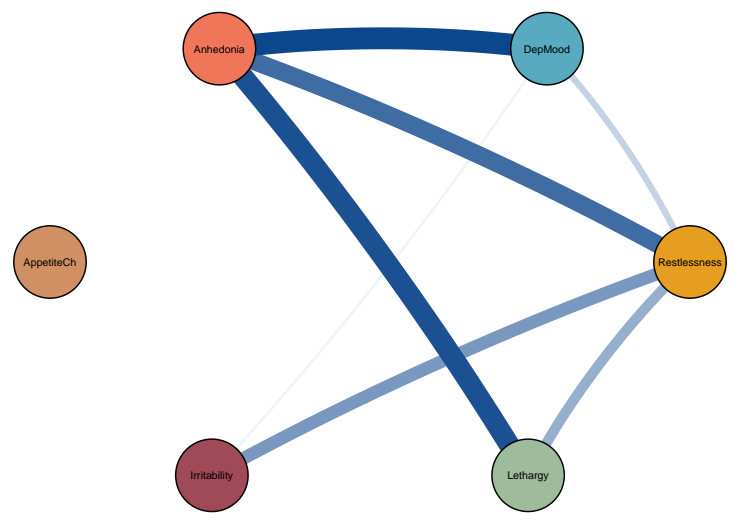


Symptom dynamics of MDD patients with IDS–SR score: 15


Patient 1: Temporal



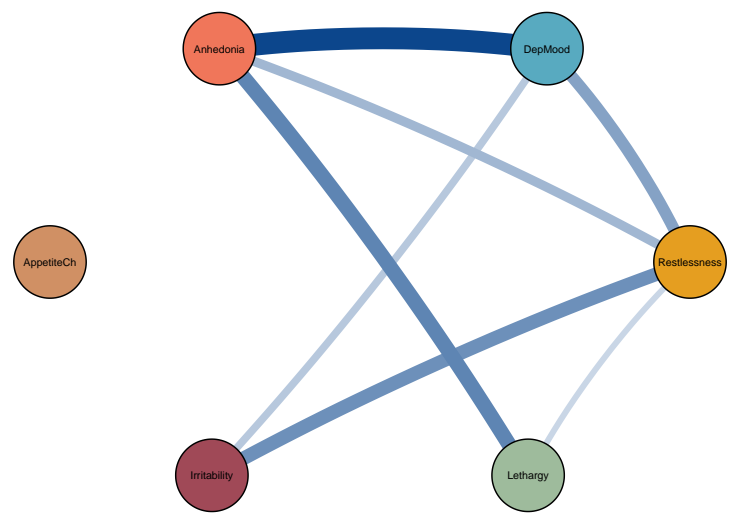
Patient 1: Contemporaneous



Patient 2: Temporal

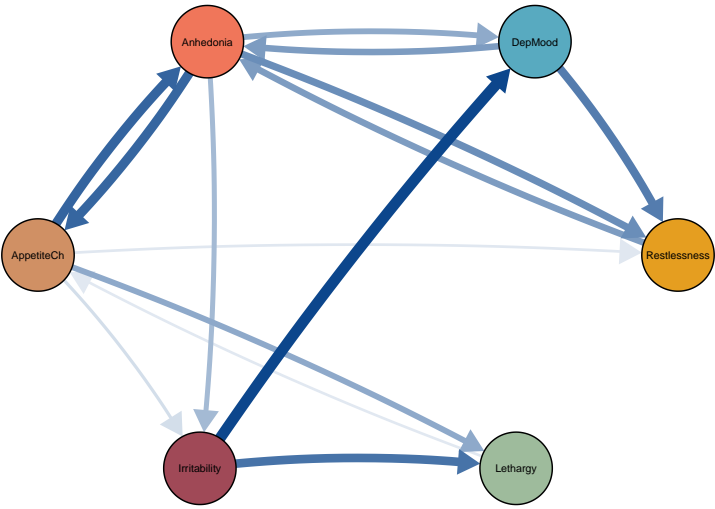


Patient 2: Contemporaneous

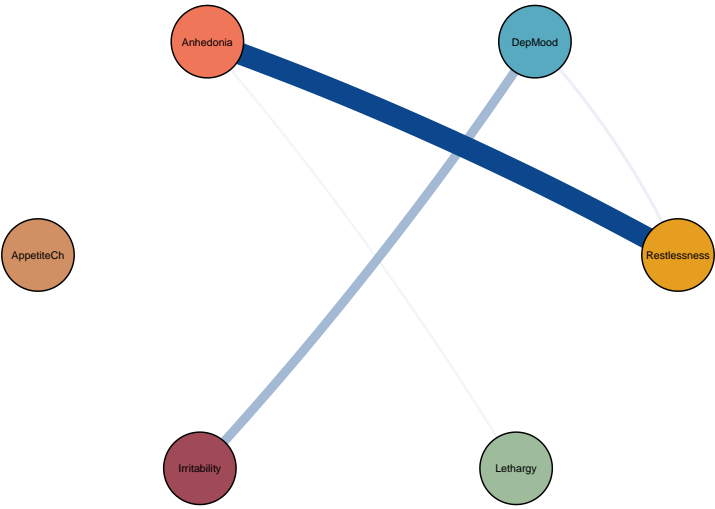


Symptom dynamics of MDD patients with IDS–SR score: 16

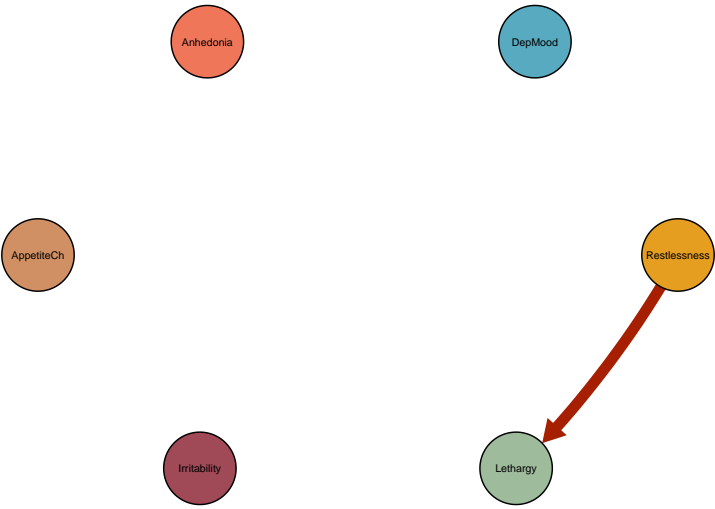Patient 3: Temporal



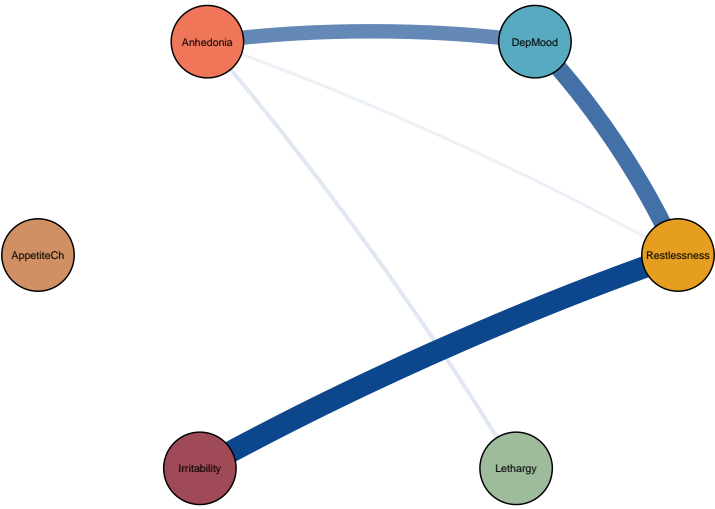
Patient 3: Contemporaneous



Patient 4: Temporal

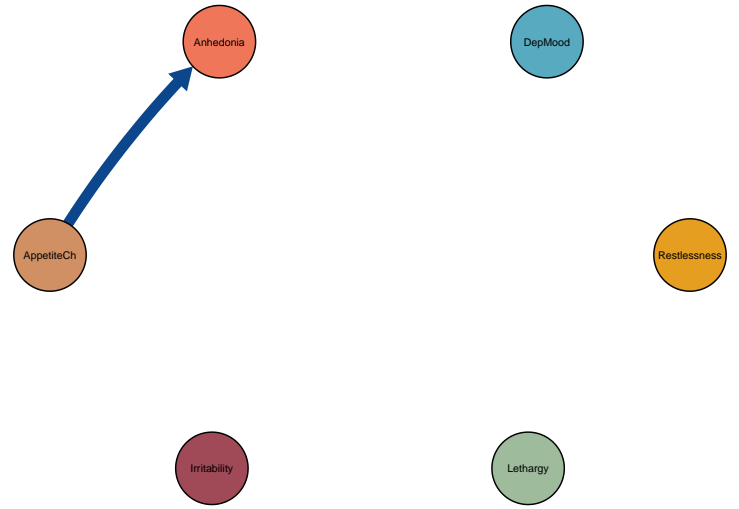

Patient 4: Contemporaneous

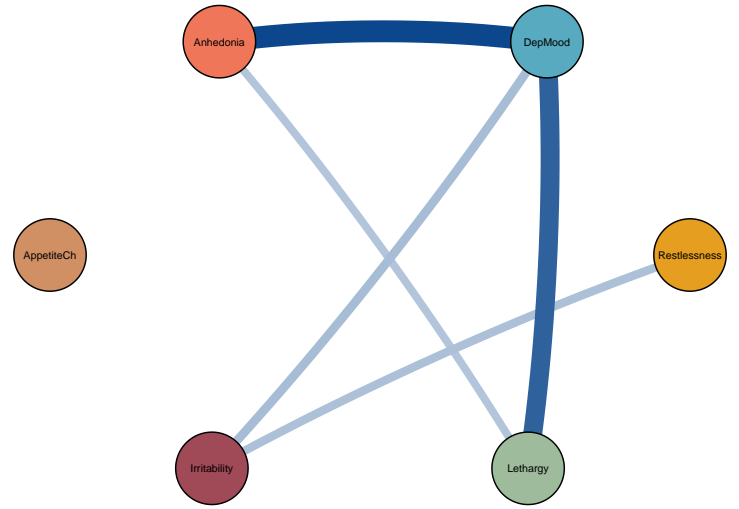


Symptom dynamics of MDD patients with IDS-SR score: 21


Patient 5: Temporal



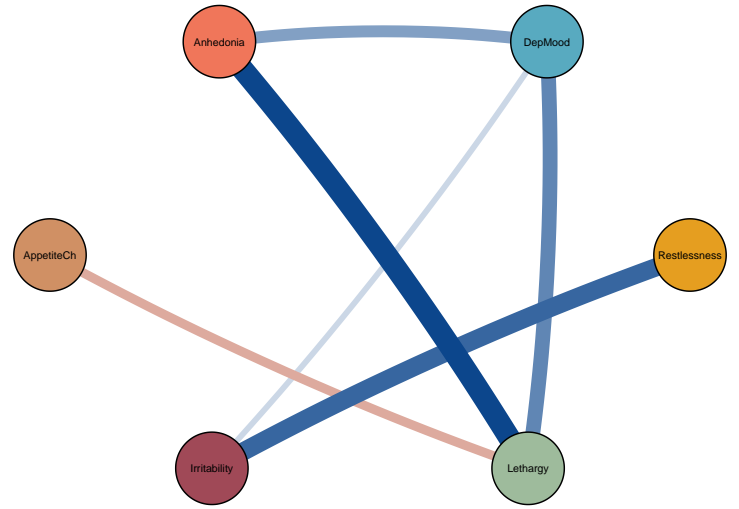
Patient 5: Contemporaneous



Patient 6: Temporal

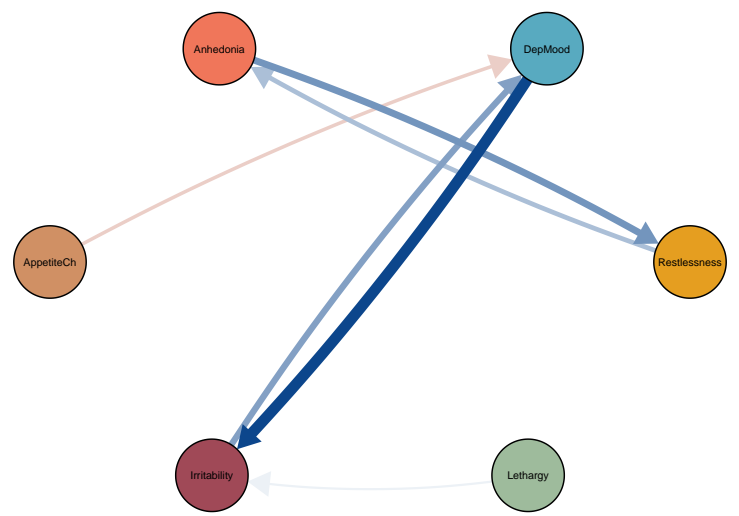


Patient 6: Contemporaneous

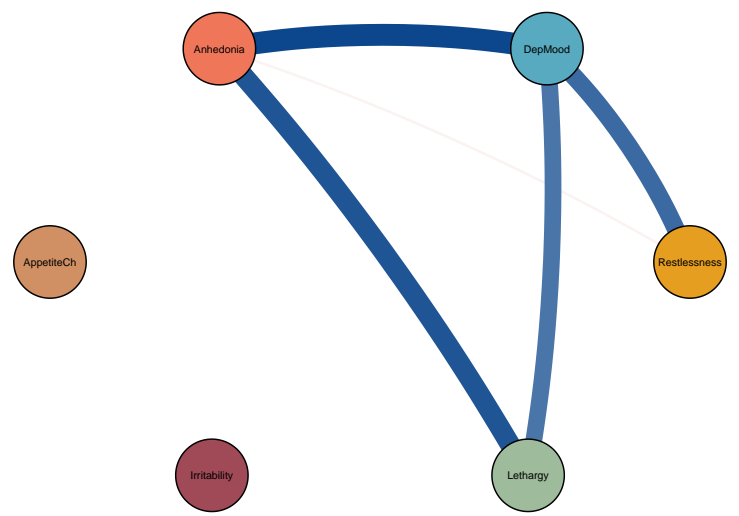


Symptom dynamics of MDD patients with IDS–SR score: 23

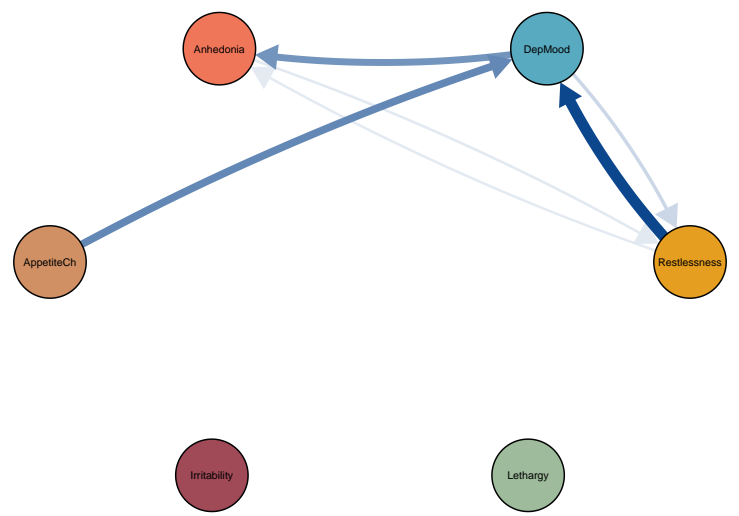
Patient 7: Temporal



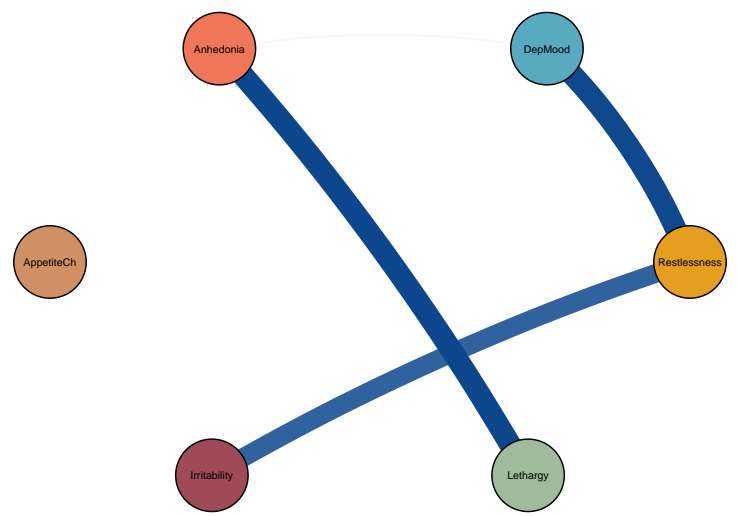
Patient 7: Contemporaneous



Patient 8: Temporal

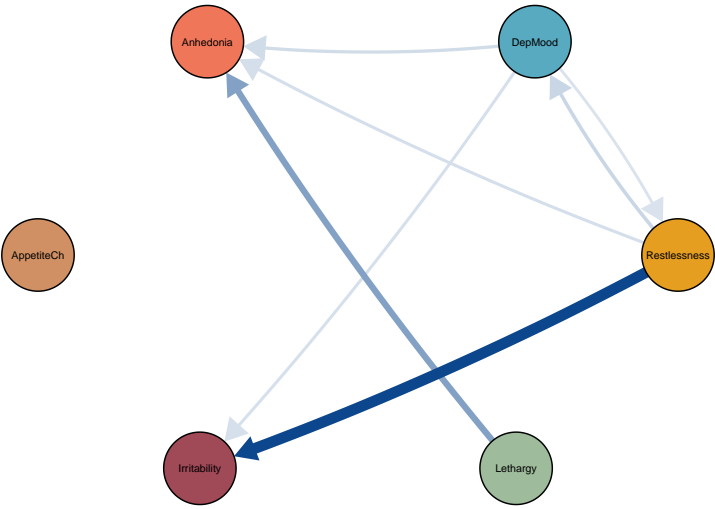


Patient 8: Contemporaneous

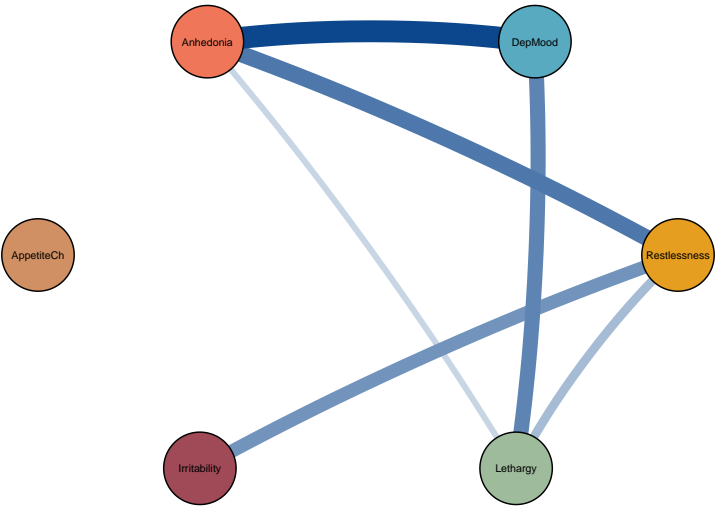


Symptom dynamics of MDD patients with IDS–SR score: 28


Patient 9: Temporal



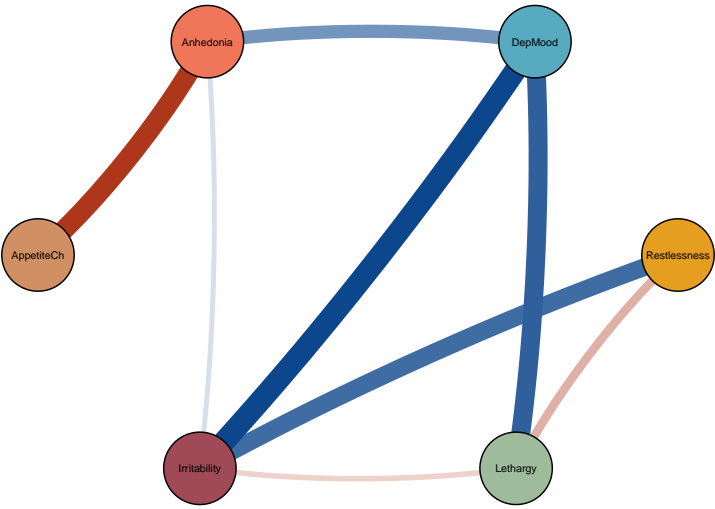
Patient 9: Contemporaneous



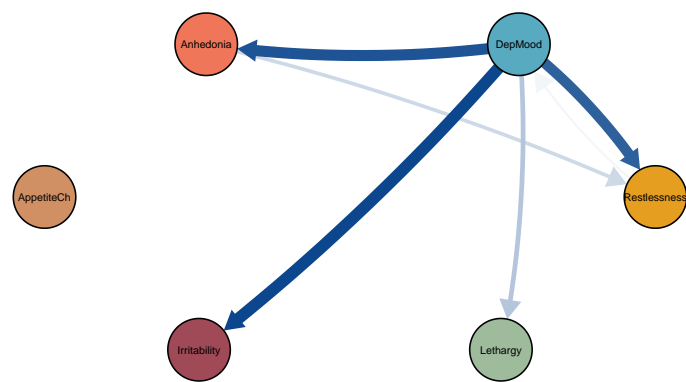
Patient 10: Temporal



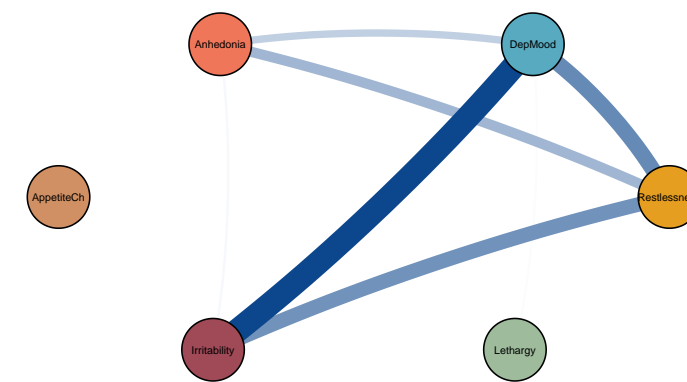
Patient 10: Contemporaneous



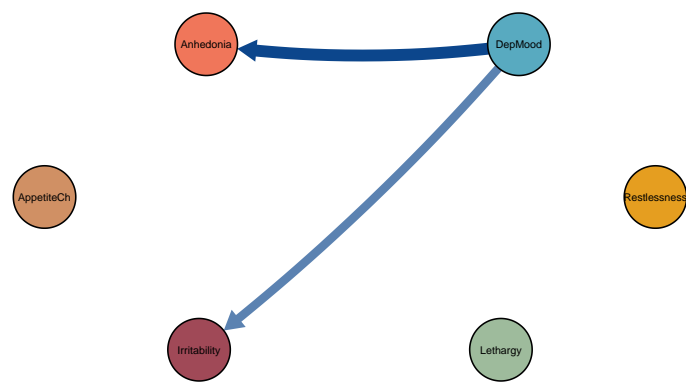
Patient 12: Temporal



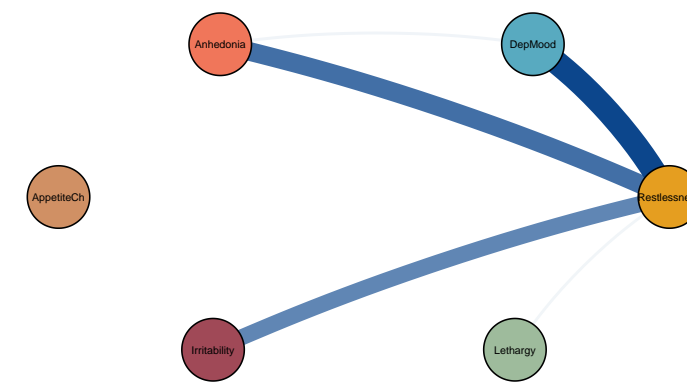
Patient 12: Contemporaneous



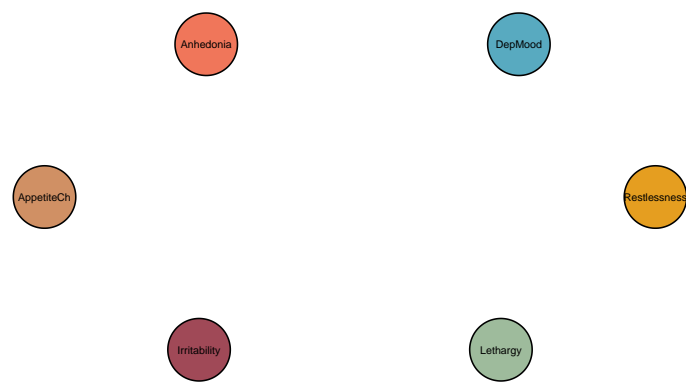Patient 13: Temporal



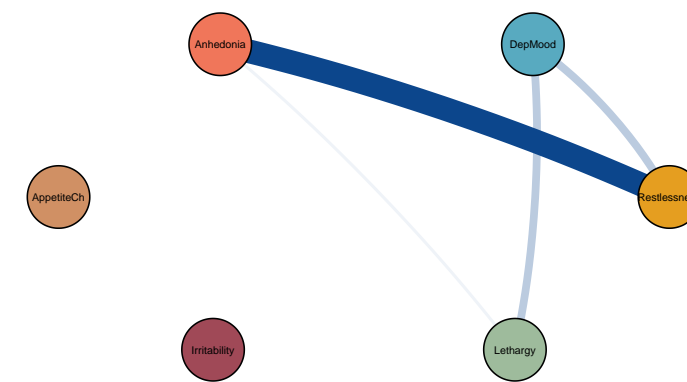
Patient 13: Contemporaneous



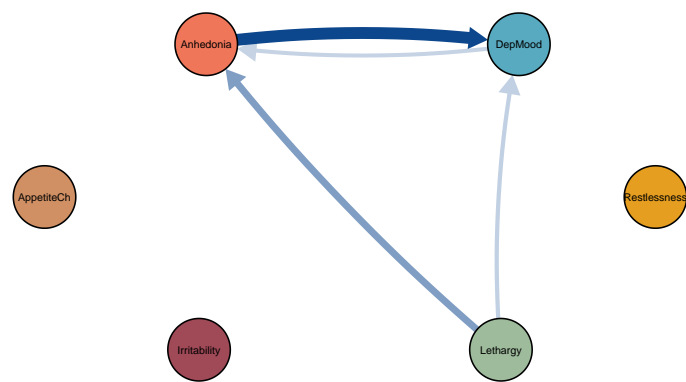
Patient 14: Temporal



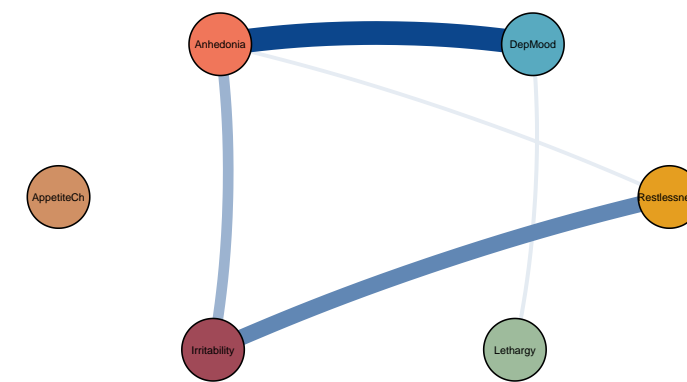
Patient 14: Contemporaneous



Patient 15: Temporal

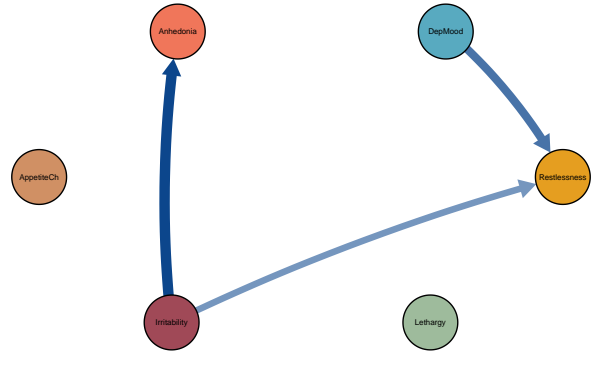


Patient 15: Contemporaneous

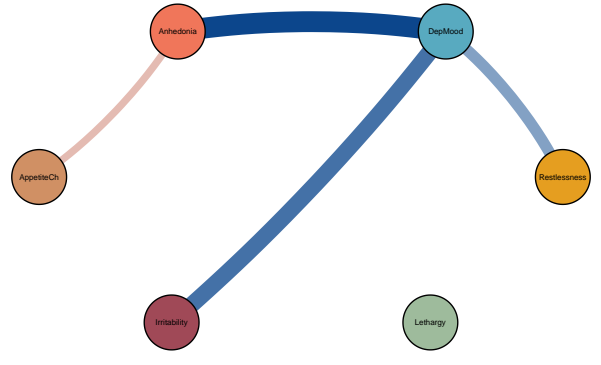


Symptom dynamics of MDD patients with IDS-SR score: 30

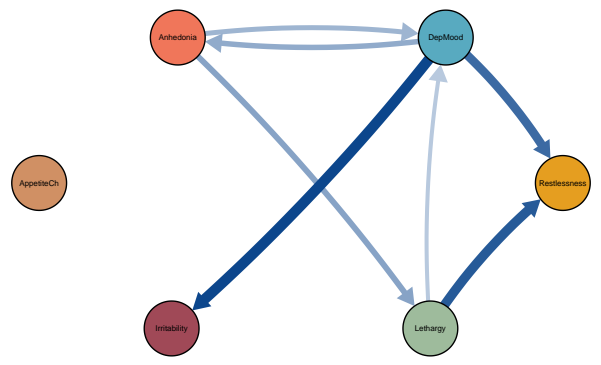
Patient 16: Temporal



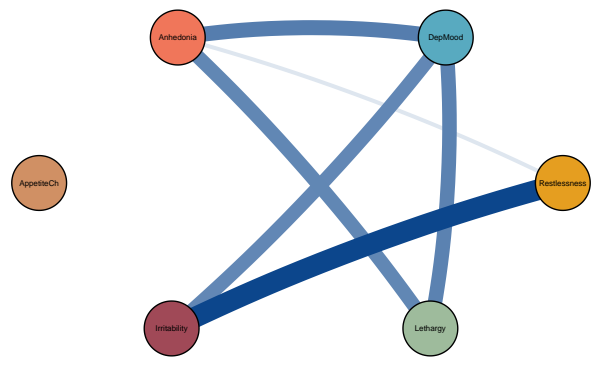
Patient 16: Contemporaneous



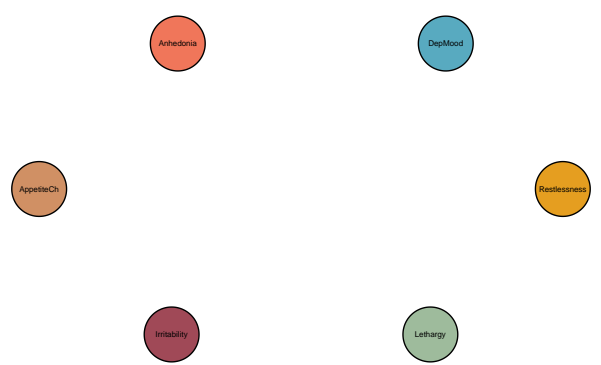
Patient 17: Temporal



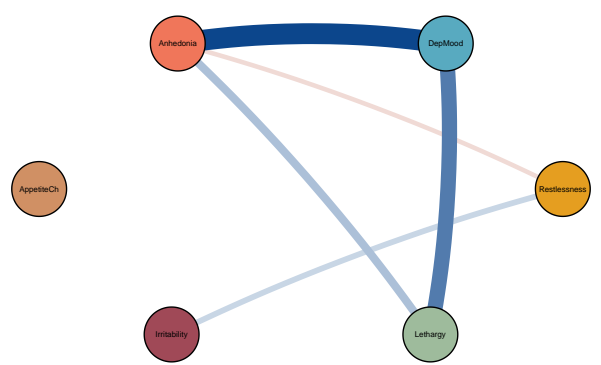
Patient 17: Contemporaneous



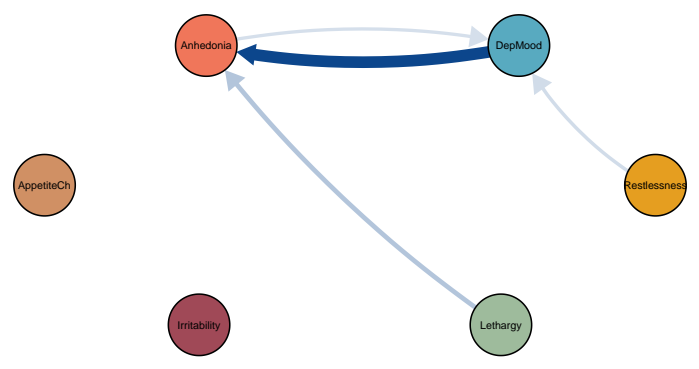
Patient 18: Temporal



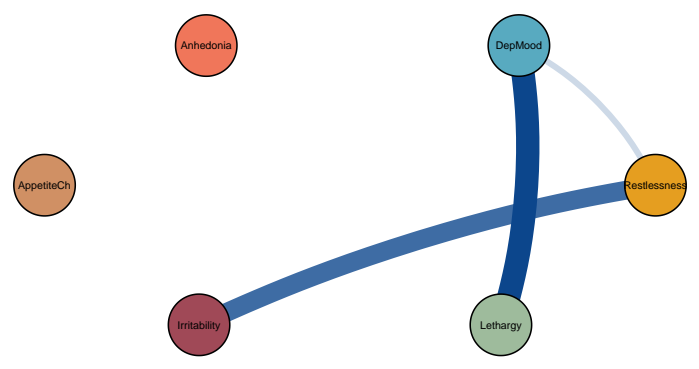
Patient 18: Contemporaneous



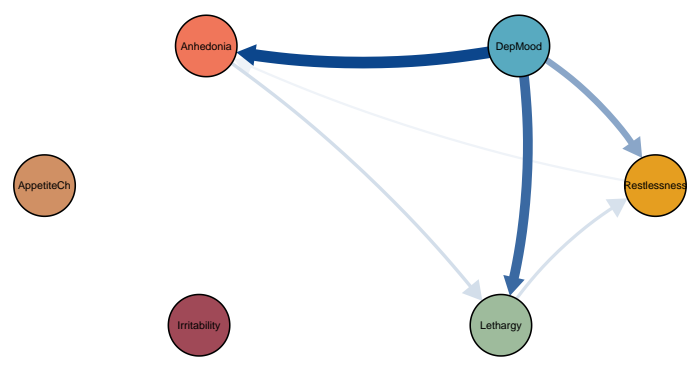
Patient 19: Temporal



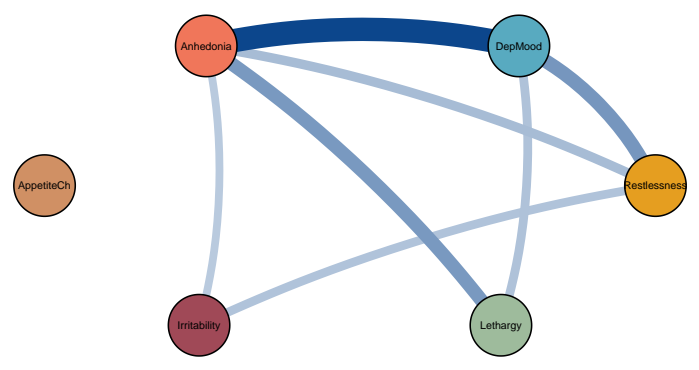
Patient 19: Contemporaneous



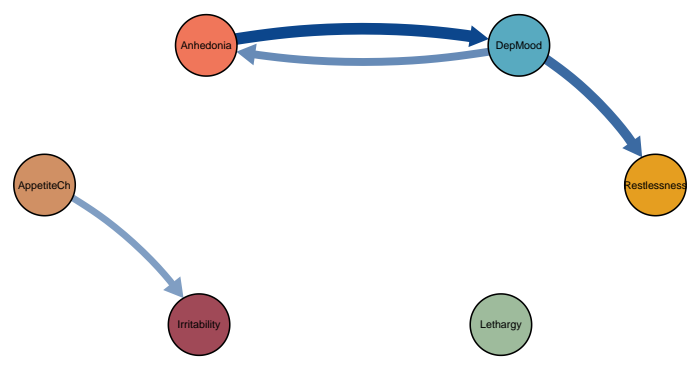
Patient 20: Temporal



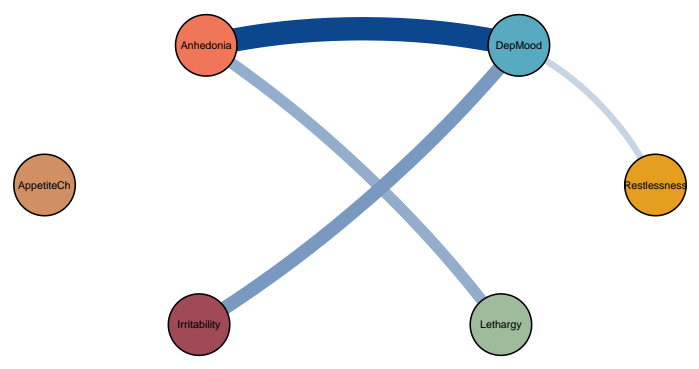
Patient 20: Contemporaneous



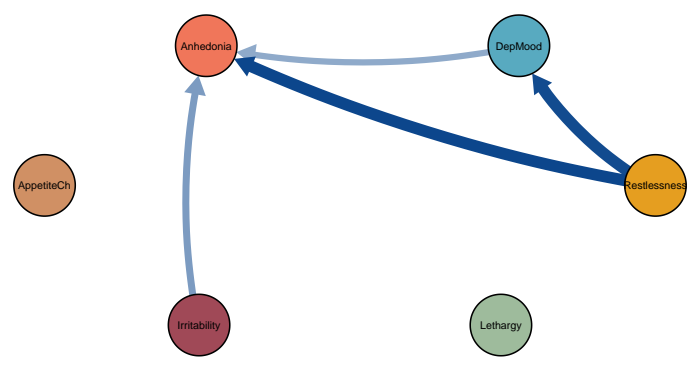
Patient 21: Temporal



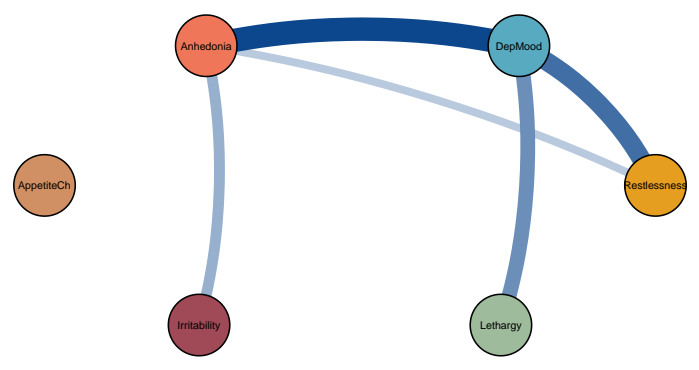
Patient 21: Contemporaneous



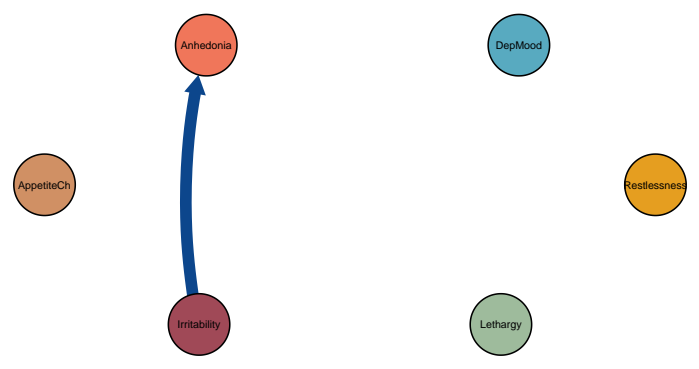
Patient 22: Temporal



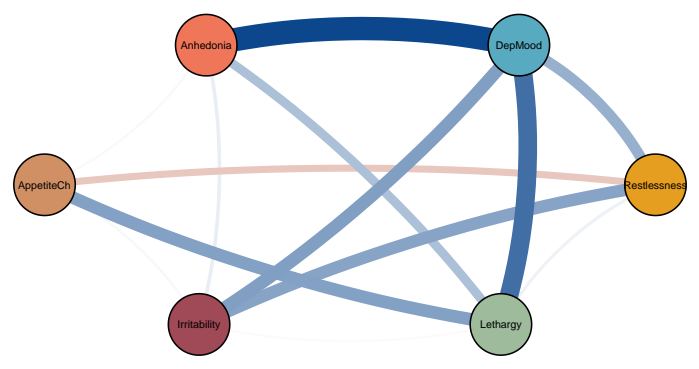
Patient 22: Contemporaneous



Patient 23: Temporal

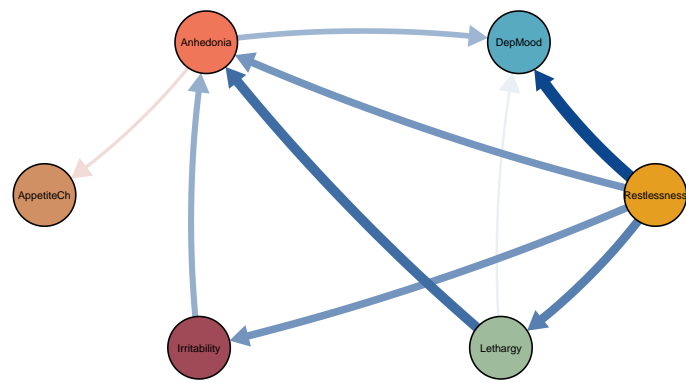


Patient 23: Contemporaneous

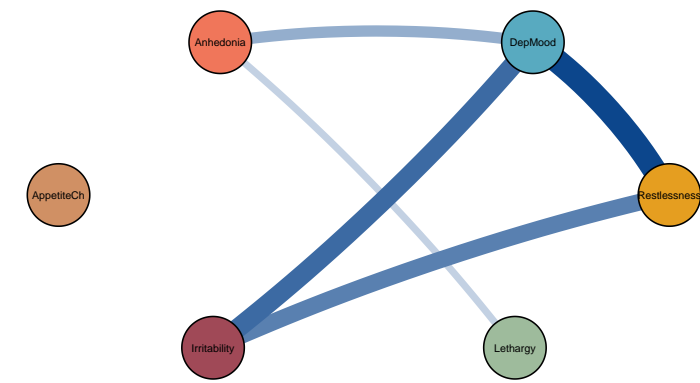




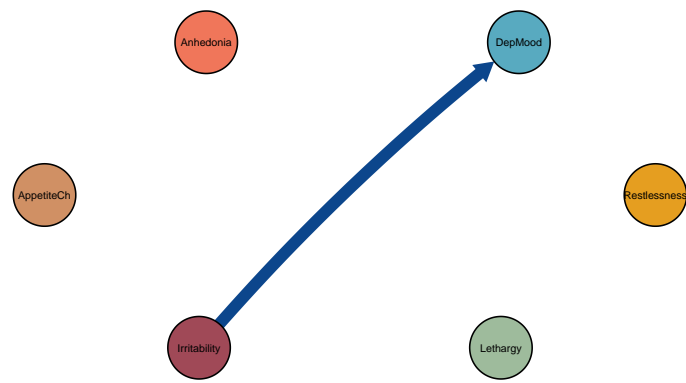
Patient 24: Temporal



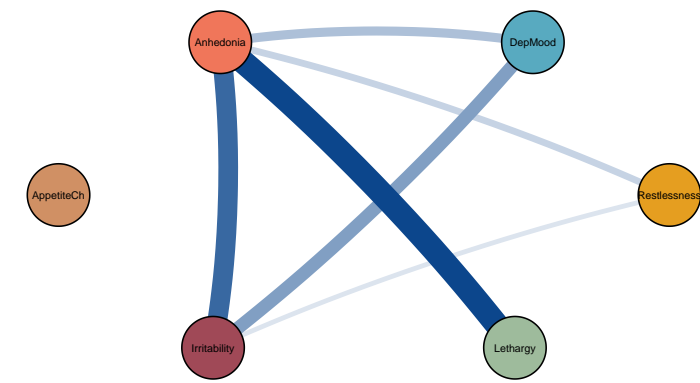
Patient 24: Contemporaneous



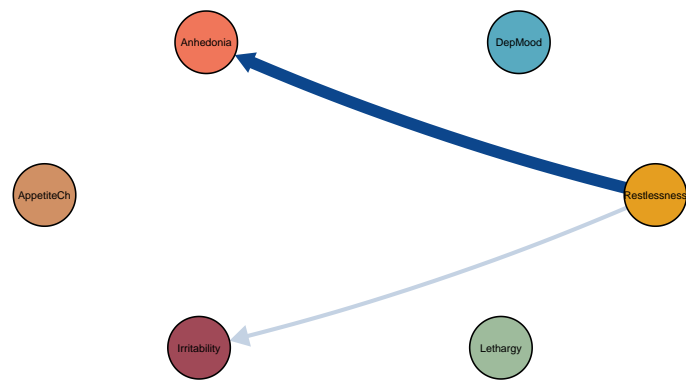
Patient 25: Temporal



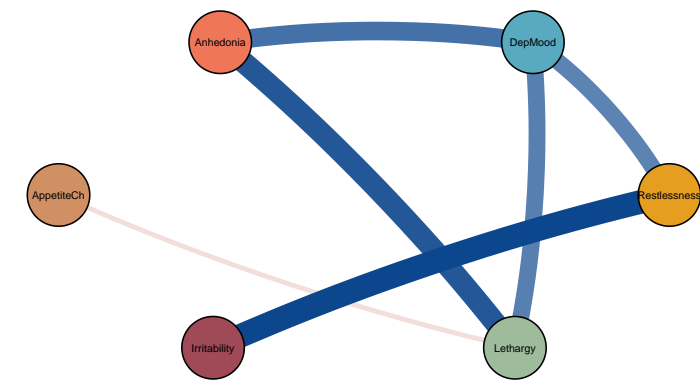
Patient 25: Contemporaneous



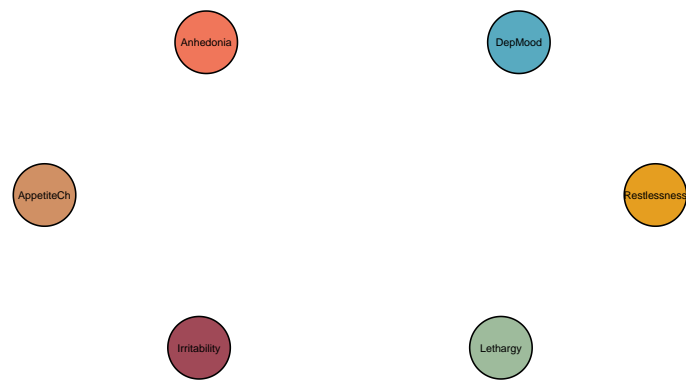
Patient 26: Temporal



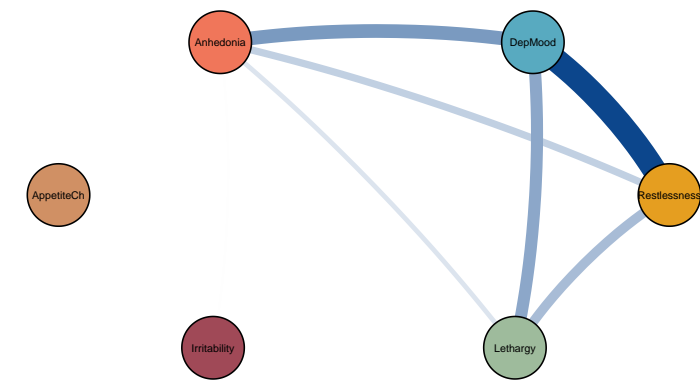
Patient 26: Contemporaneous



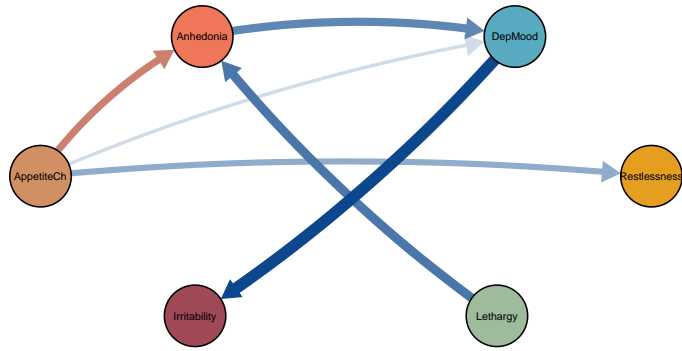
Patient 27: Temporal



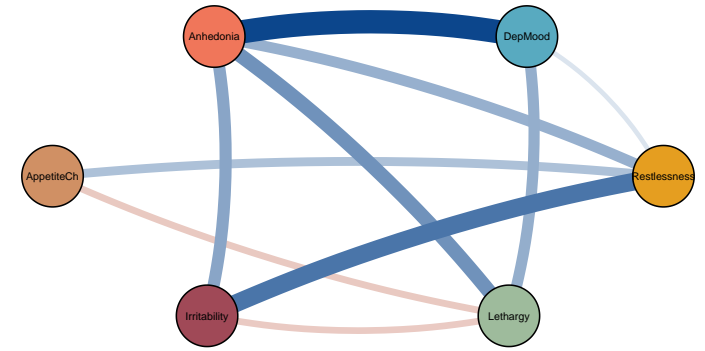
Patient 27: Contemporaneous



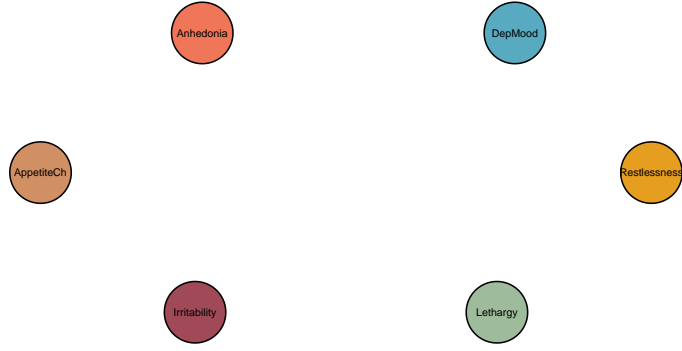
Patient 28: Temporal



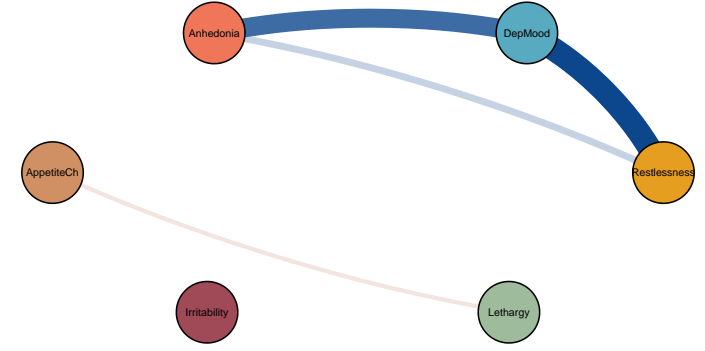
Patient 28: Contemporaneous



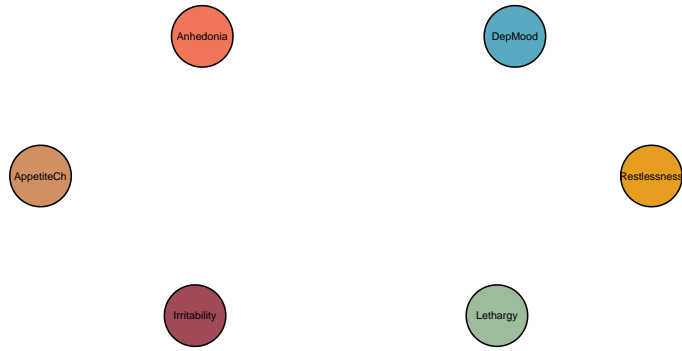
Patient 29: Temporal



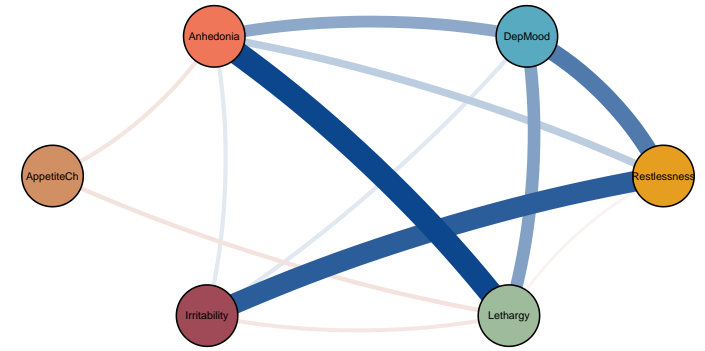
Patient 29: Contemporaneous



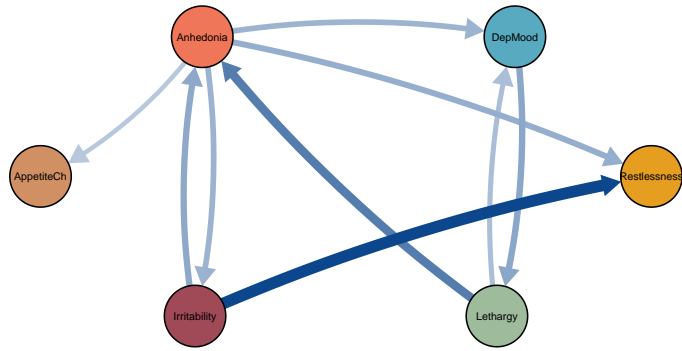
Patient 30: Temporal



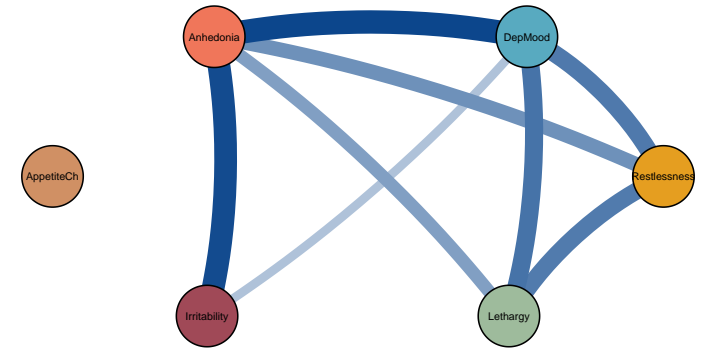
Patient 30: Contemporaneous



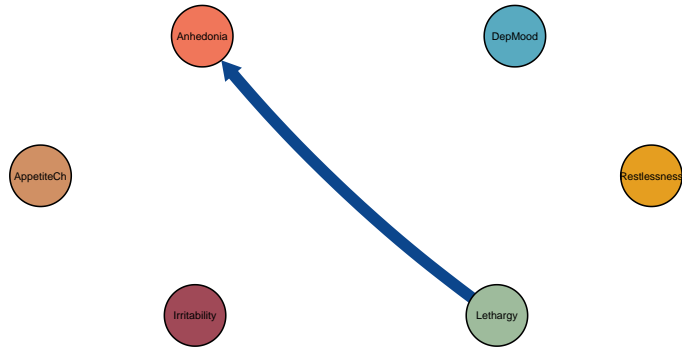
Patient 31: Temporal



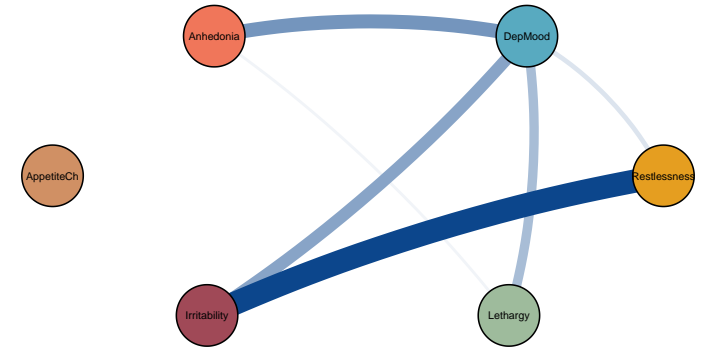
Patient 31: Contemporaneous



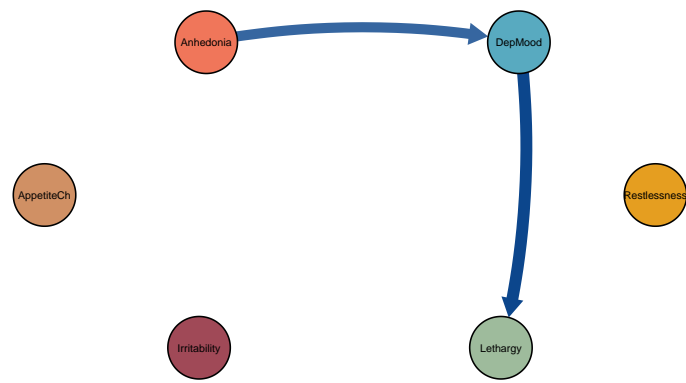
Patient 32: Temporal



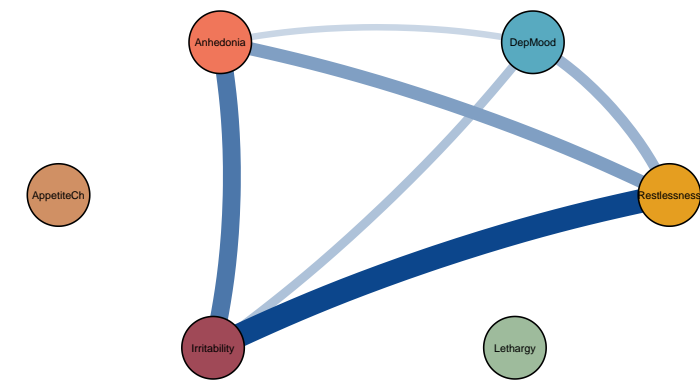
Patient 32: Contemporaneous



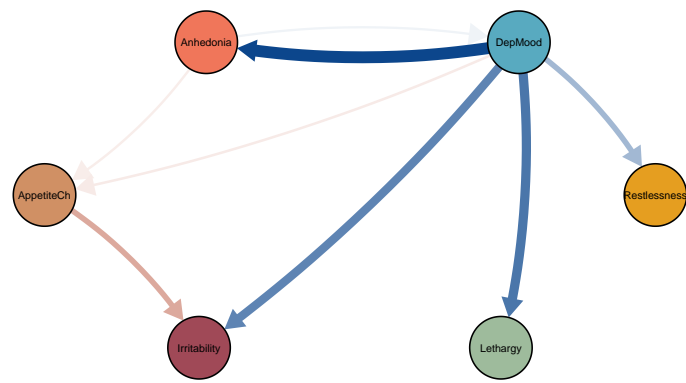
Patient 33: Temporal



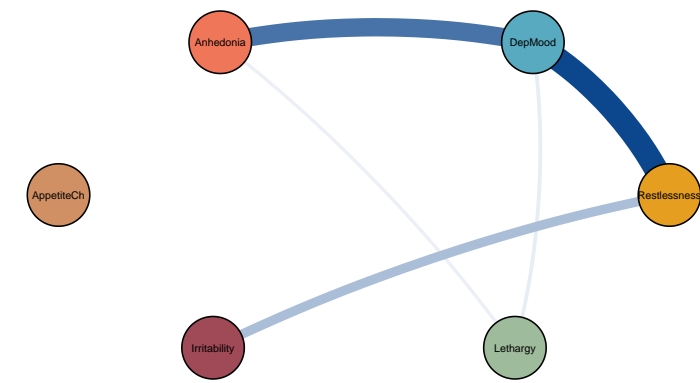
Patient 33: Contemporaneous



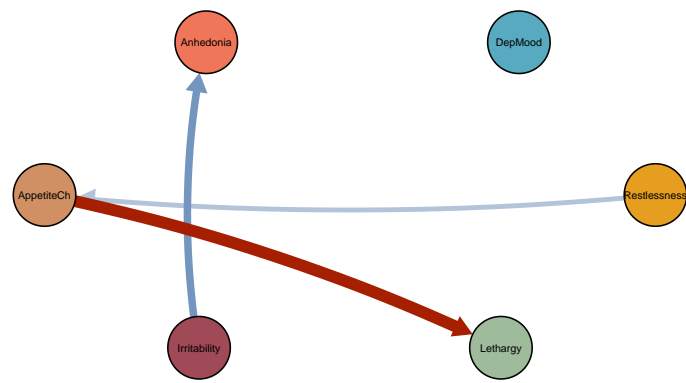
Patient 34: Temporal



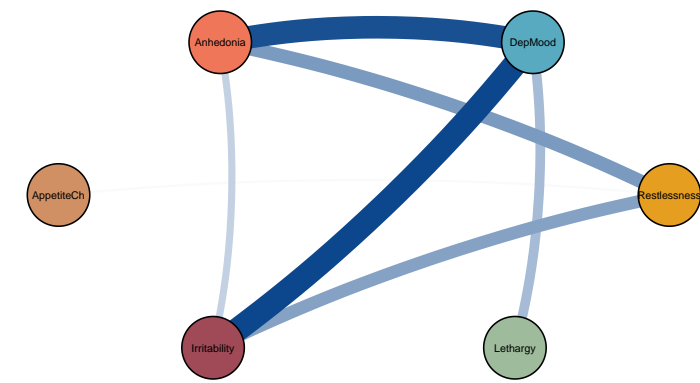
Patient 34: Contemporaneous



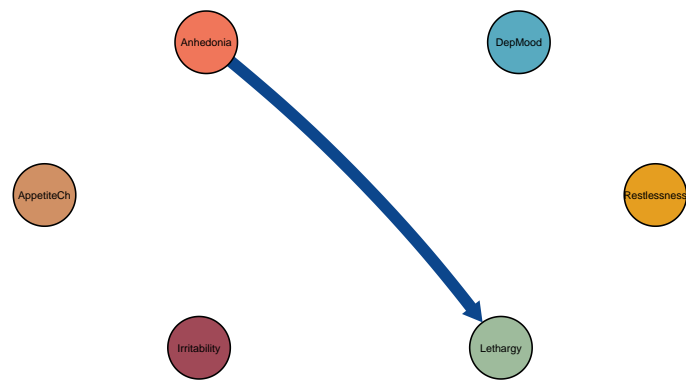
Patient 35: Temporal



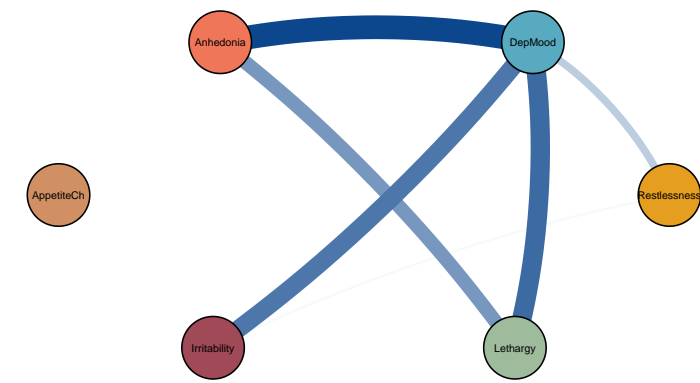
Patient 35: Contemporaneous



Patient 36: Temporal

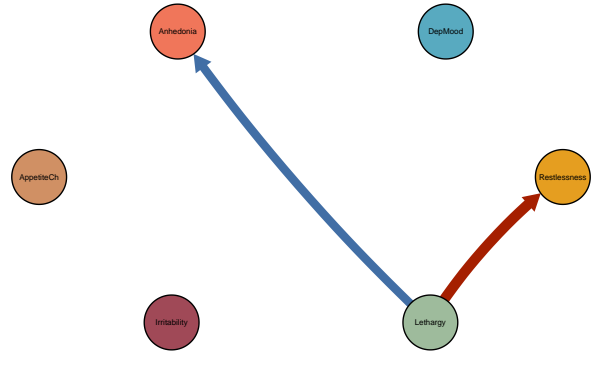


Patient 36: Contemporaneous

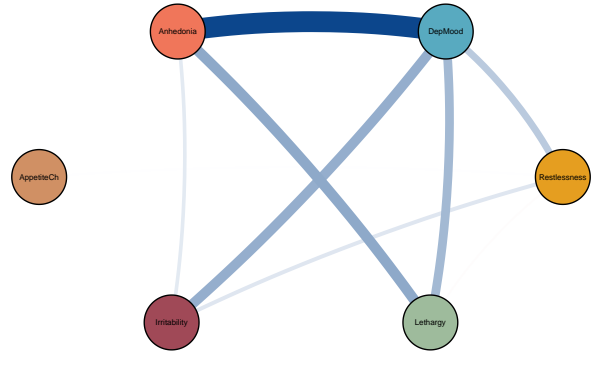


Symptom dynamics of MDD patients with IDS-SR score: 35

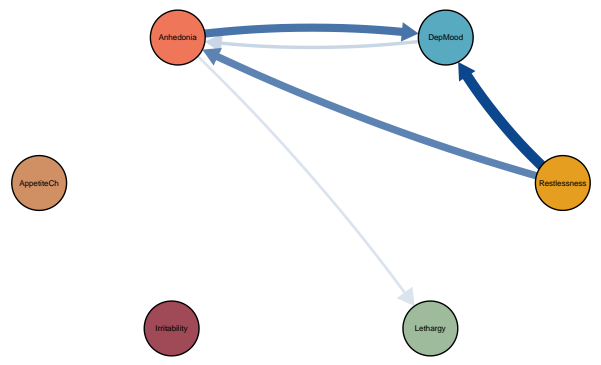
Patient 37: Temporal



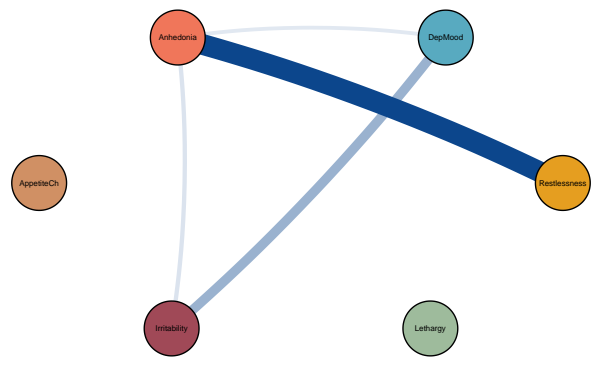
Patient 37: Contemporaneous



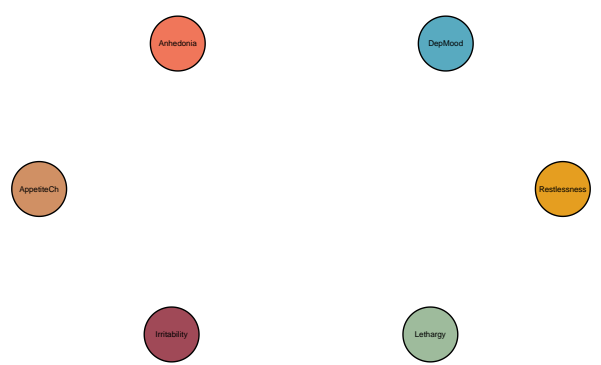
Patient 38: Temporal



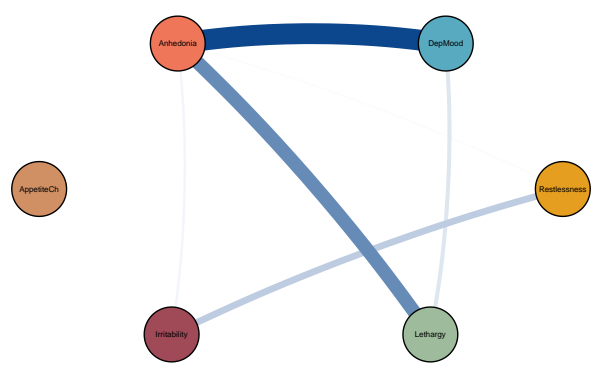
Patient 38: Contemporaneous



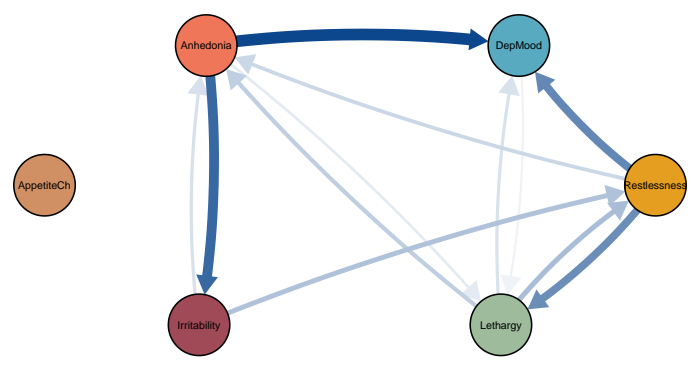
Patient 39: Temporal



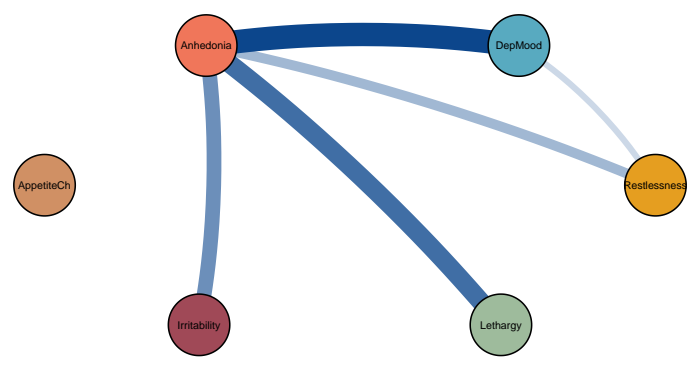
Patient 39: Contemporaneous



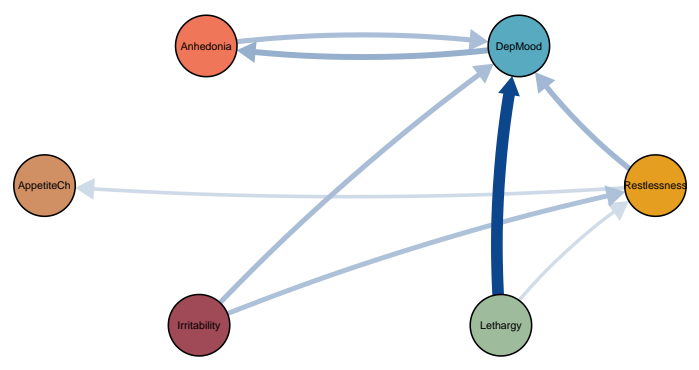
Patient 40: Temporal



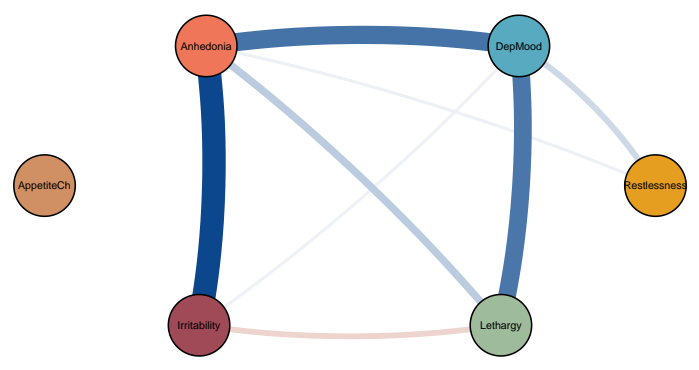
Patient 40: Contemporaneous



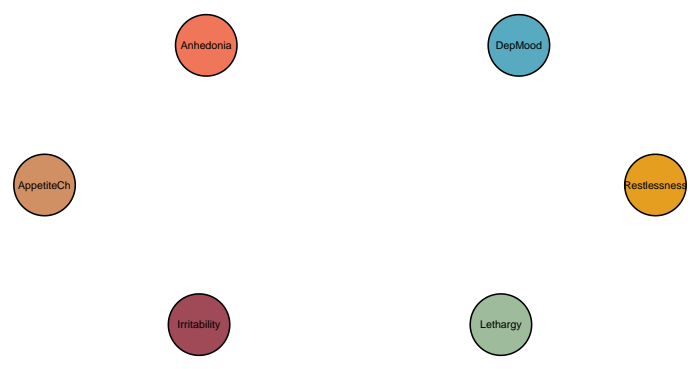Patient 41: Temporal



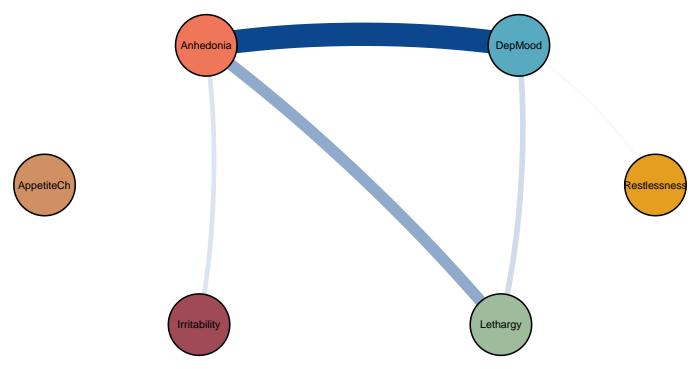
Patient 41: Contemporaneous



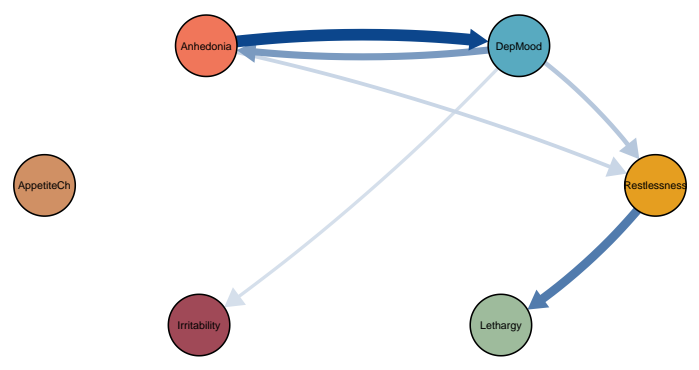
Patient 42: Temporal



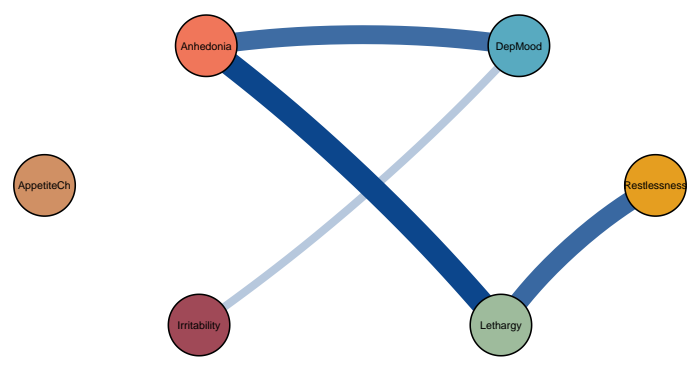
Patient 42: Contemporaneous



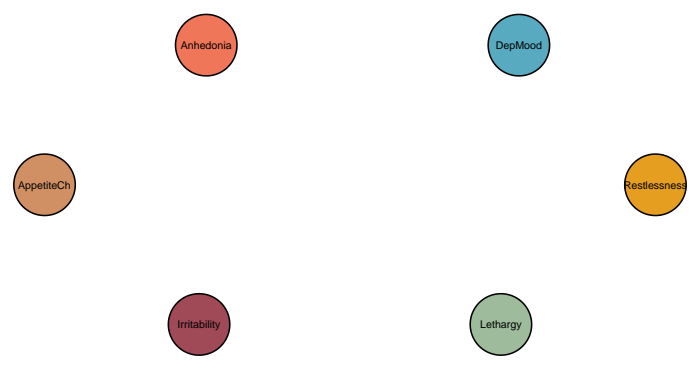
Patient 43: Temporal



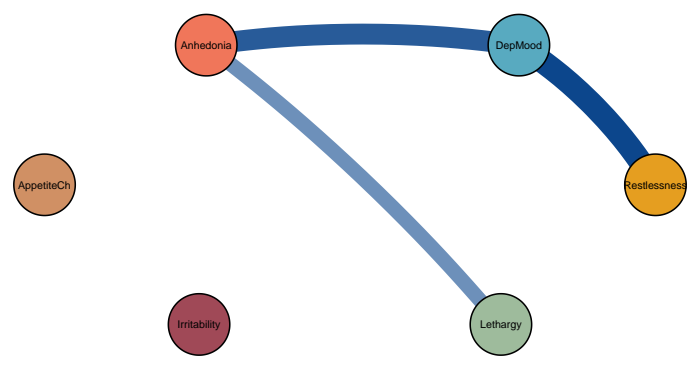
Patient 43: Contemporaneous



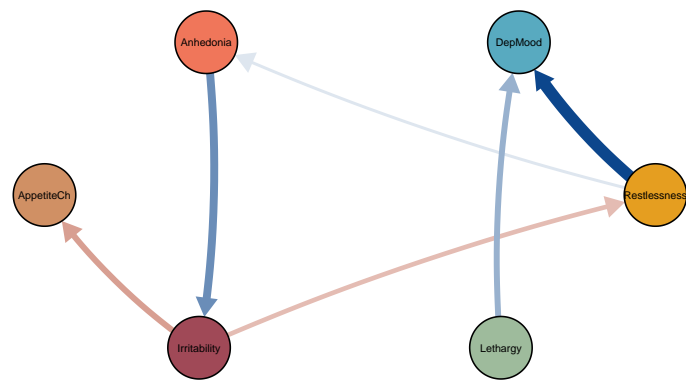
Patient 44: Temporal



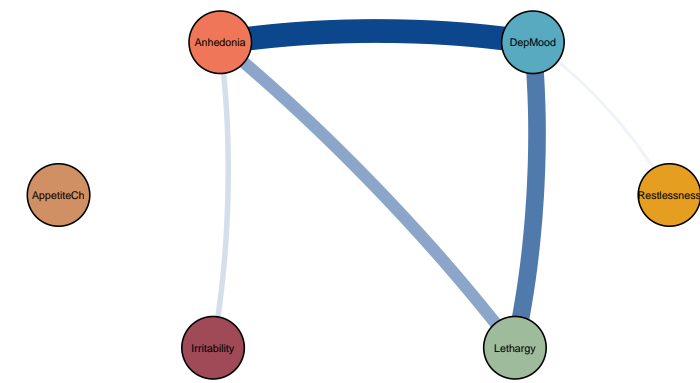
Patient 44: Contemporaneous



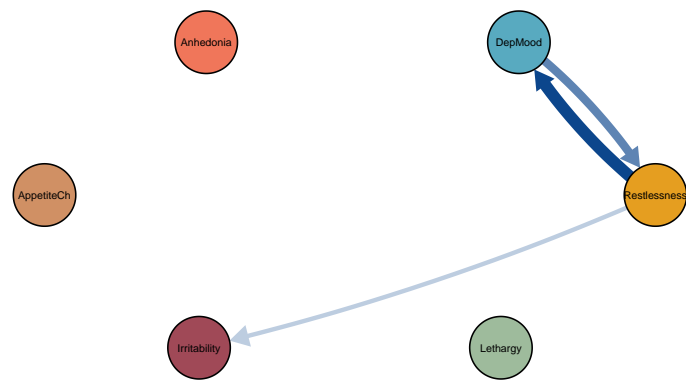
Patient 45: Temporal



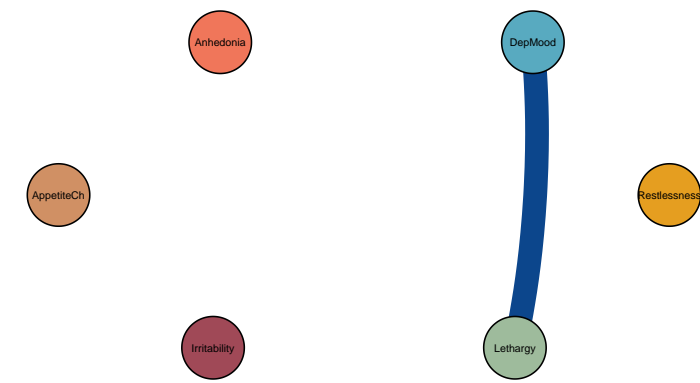
Patient 45: Contemporaneous



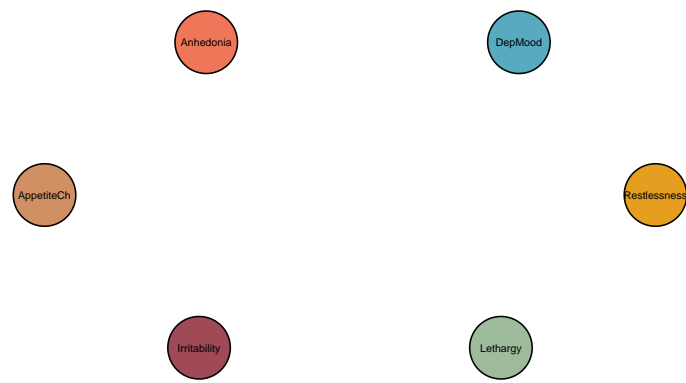Patient 46: Temporal



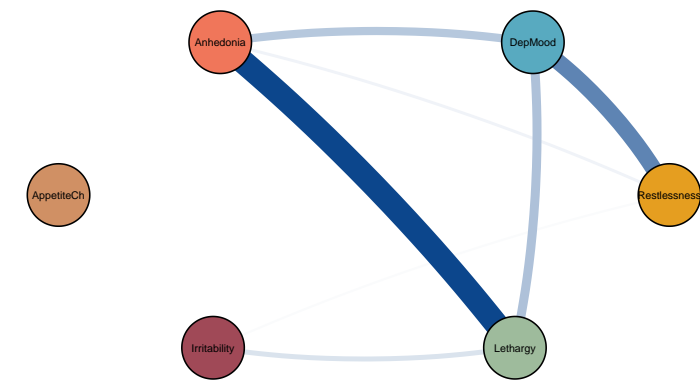
Patient 46: Contemporaneous



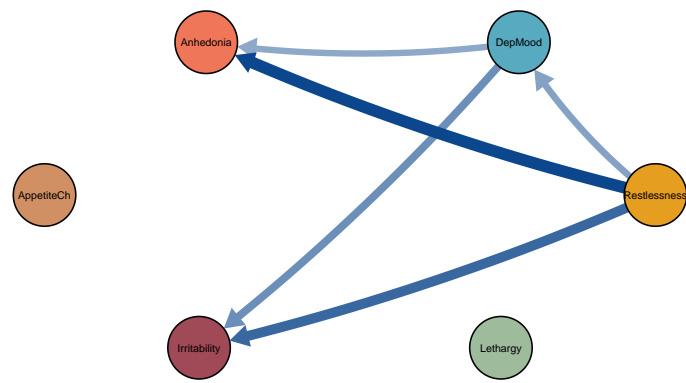
Patient 47: Temporal



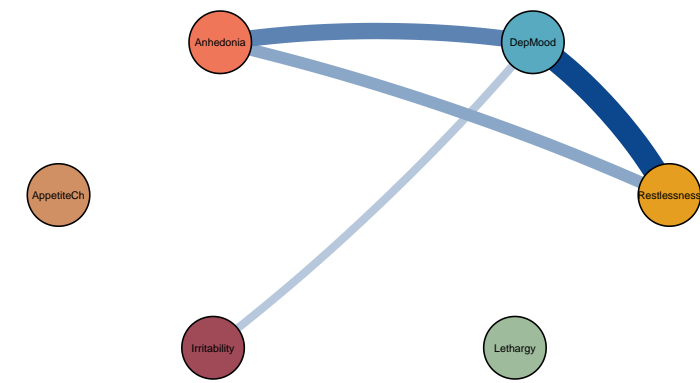
Patient 47: Contemporaneous



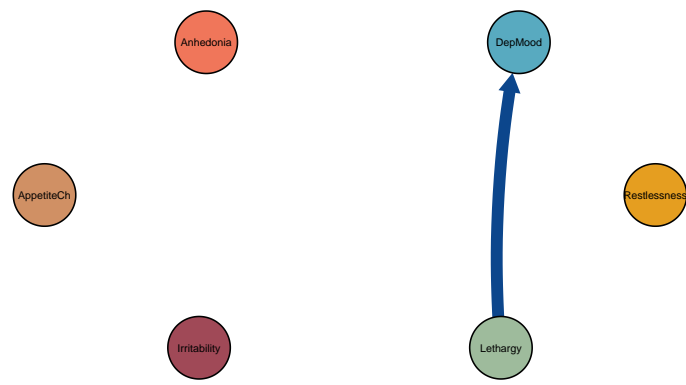
Patient 48: Temporal



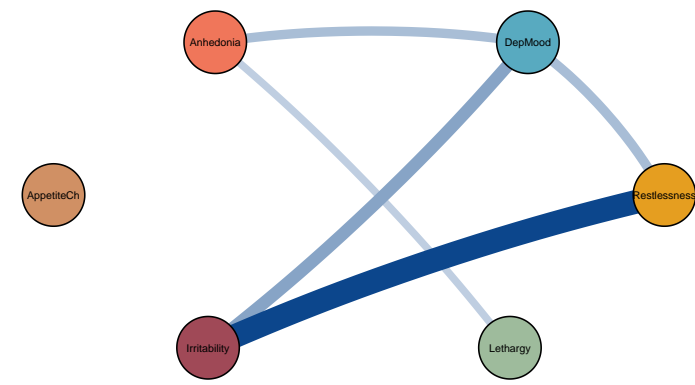
Patient 48: Contemporaneous



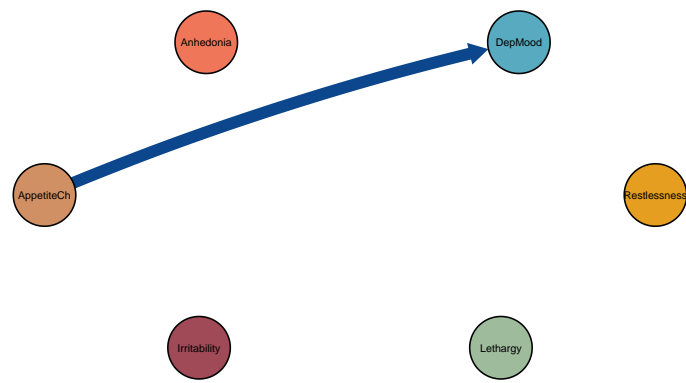
Patient 49: Temporal



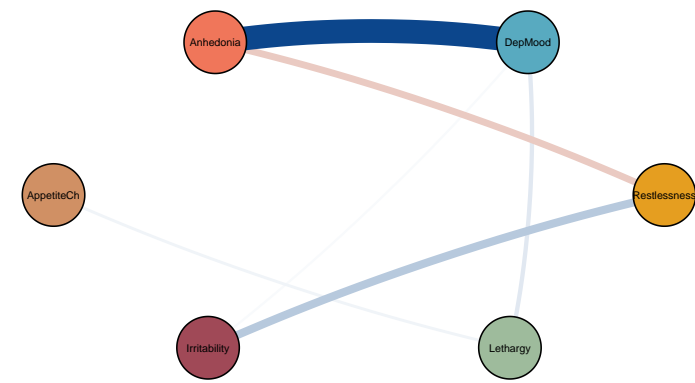
Patient 49: Contemporaneous



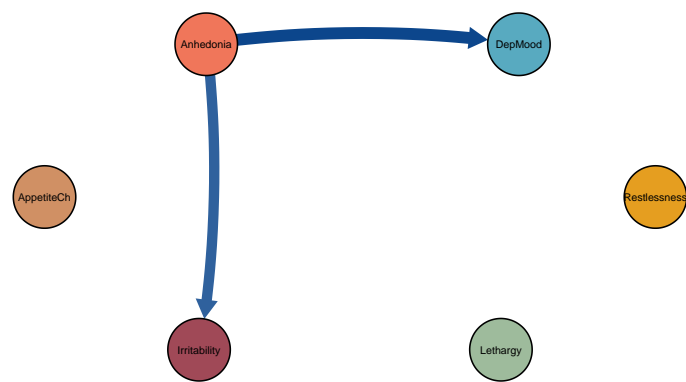
Patient 50: Temporal



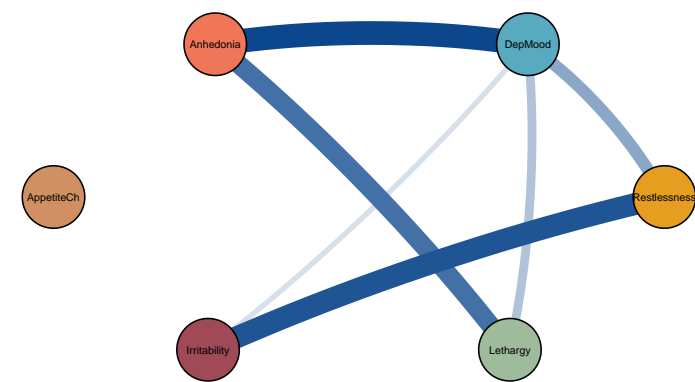
Patient 50: Contemporaneous



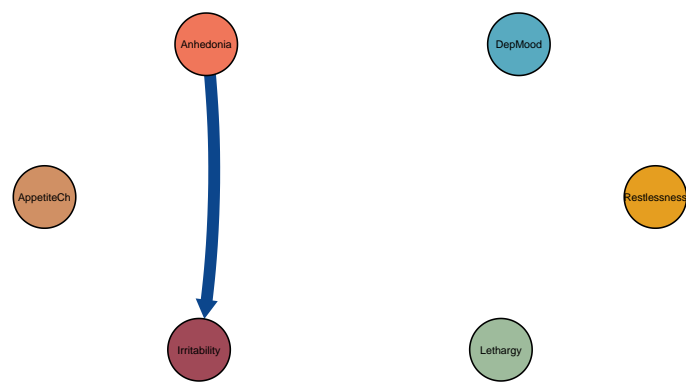
Patient 51: Temporal



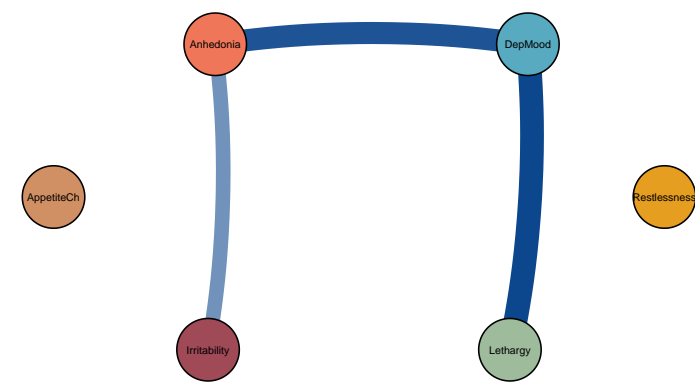
Patient 51: Contemporaneous



Patient 52: Temporal

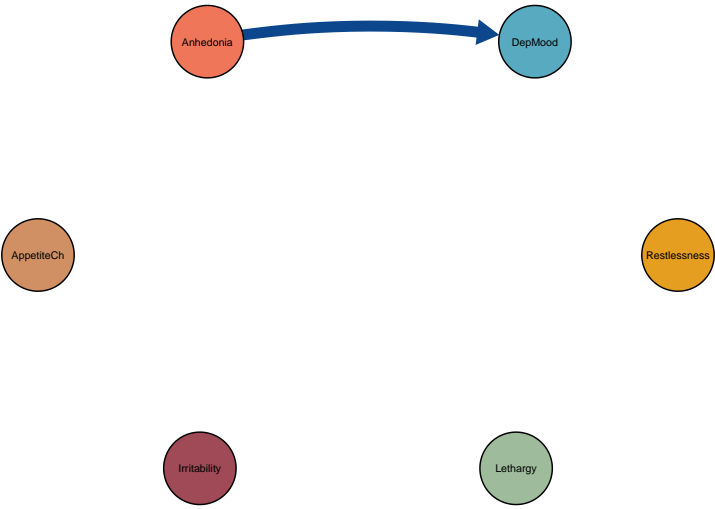


Patient 52: Contemporaneous

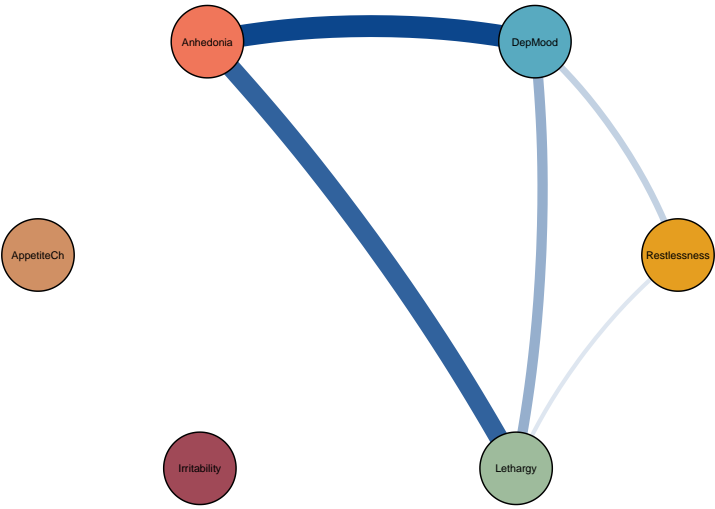


Symptom dynamics of MDD patients with IDS-SR score: 41

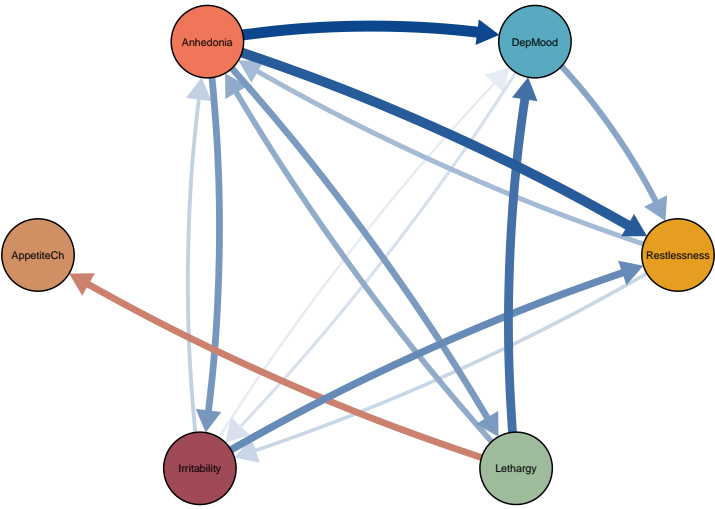
Patient 53: Temporal



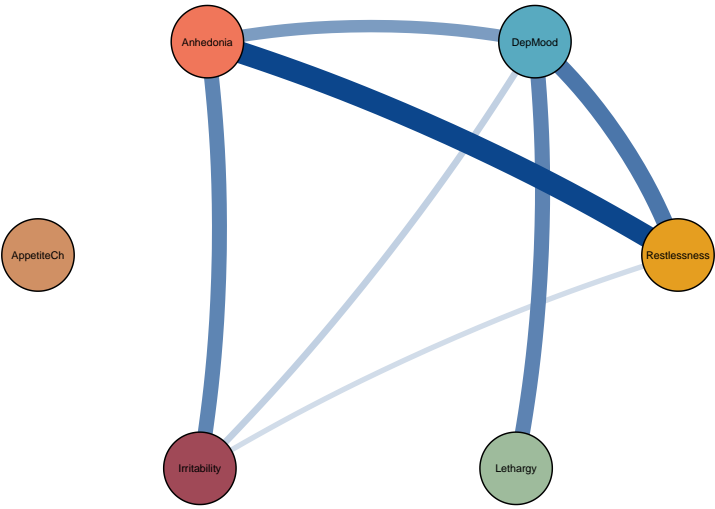
Patient 53: Contemporaneous



Patient 54: Temporal




Patient 54: Contemporaneous



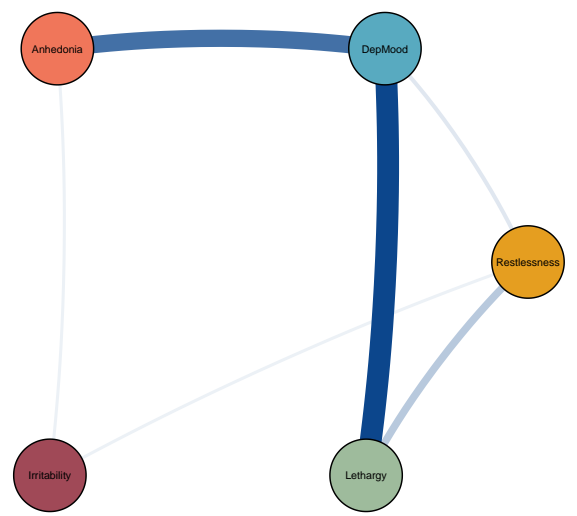


Symptom dynamics of MDD patients with IDS–SR score: 43


Patient 55: Temporal



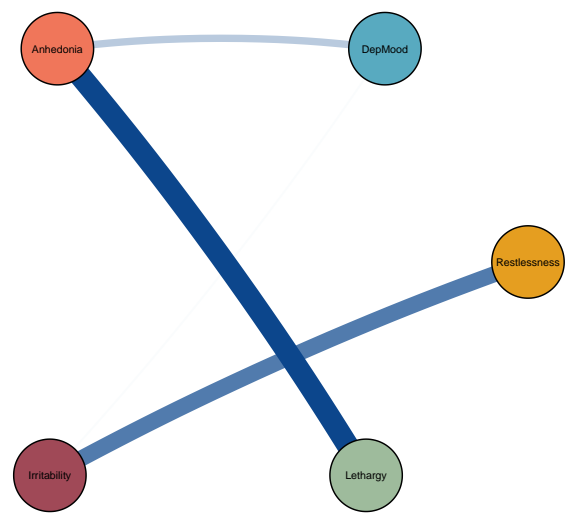
Patient 55: Contemporaneous



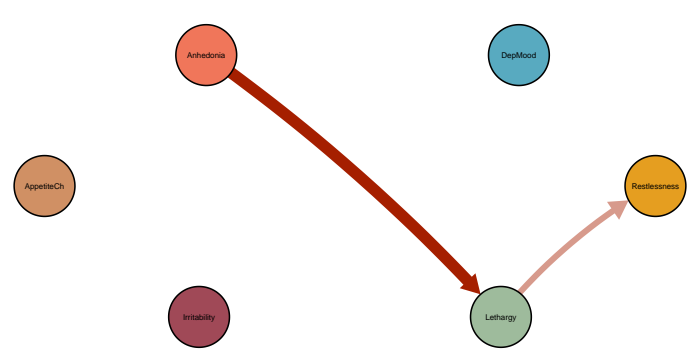
Patient 56: Temporal



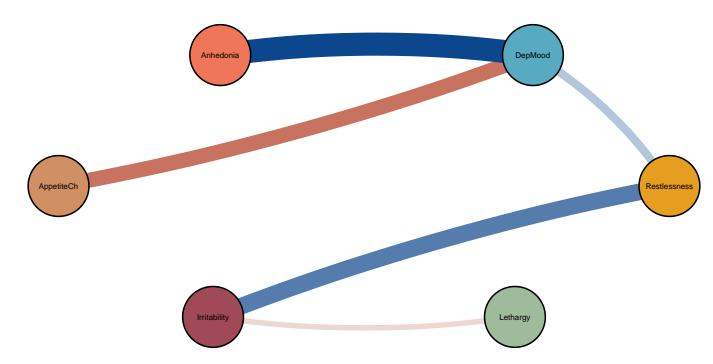
Patient 56: Contemporaneous



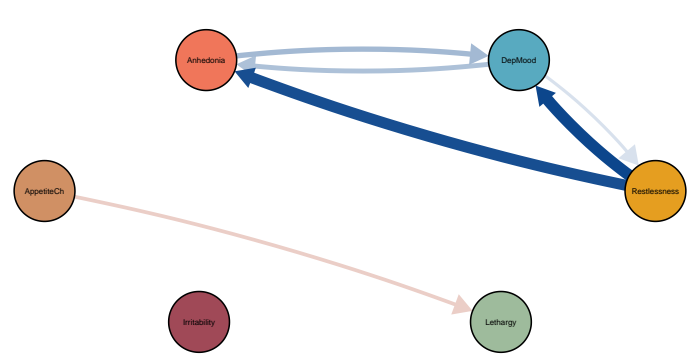
Patient 57: Temporal



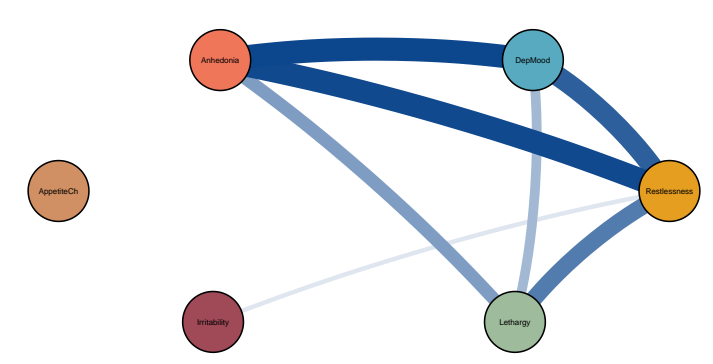
Patient 57: Contemporaneous



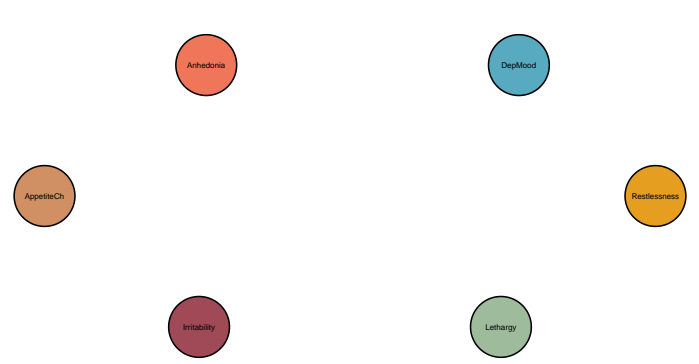Patient 58: Temporal



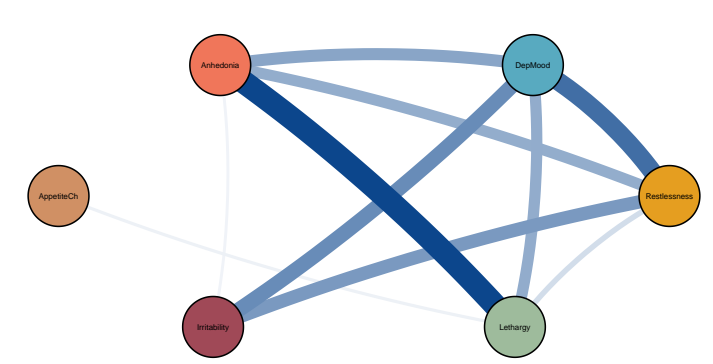
Patient 58: Contemporaneous



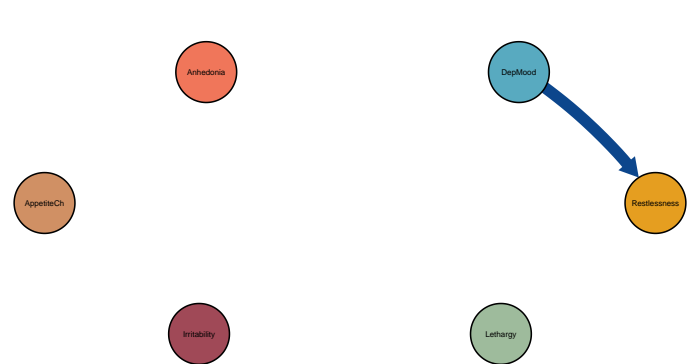Patient 59: Temporal



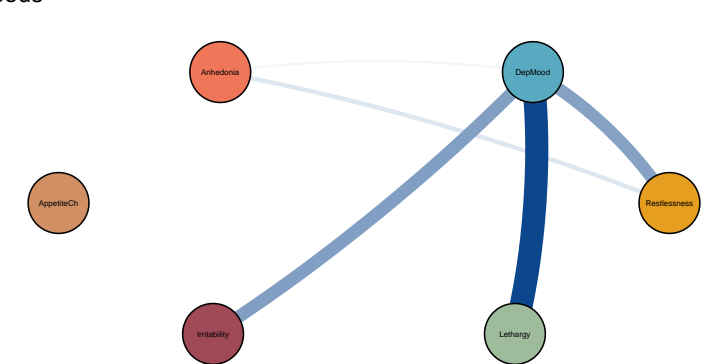
Patient 59: Contemporaneous



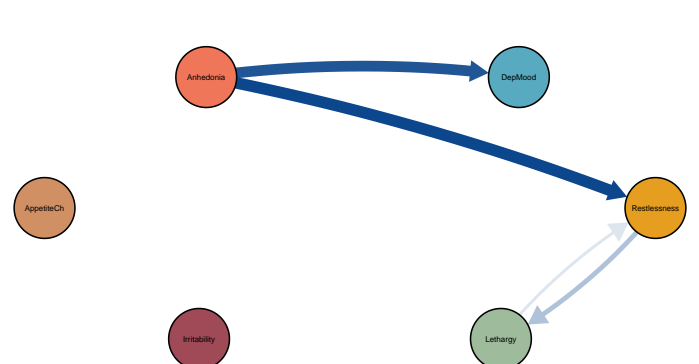Patient 60: Temporal



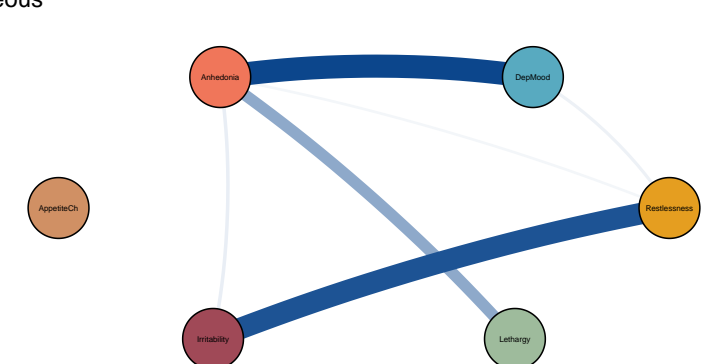
Patient 60: Contemporaneous



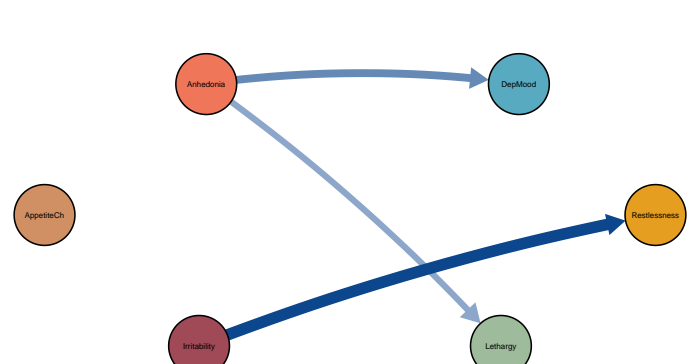
Patient 61: Temporal



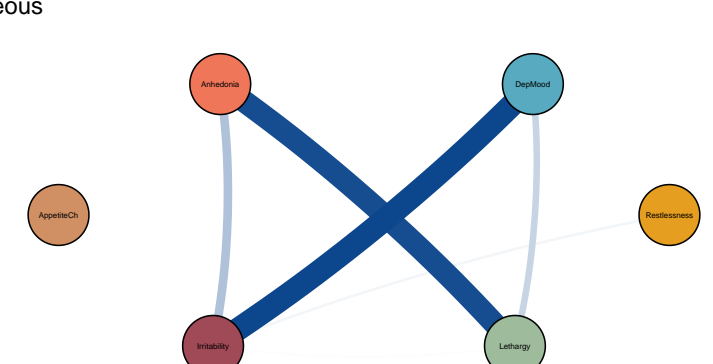
Patient 61: Contemporaneous



Patient 62: Temporal

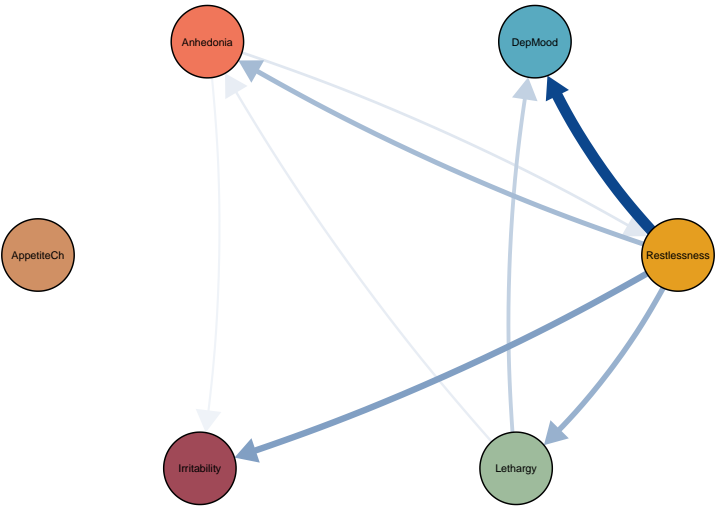


Patient 62: Contemporaneous

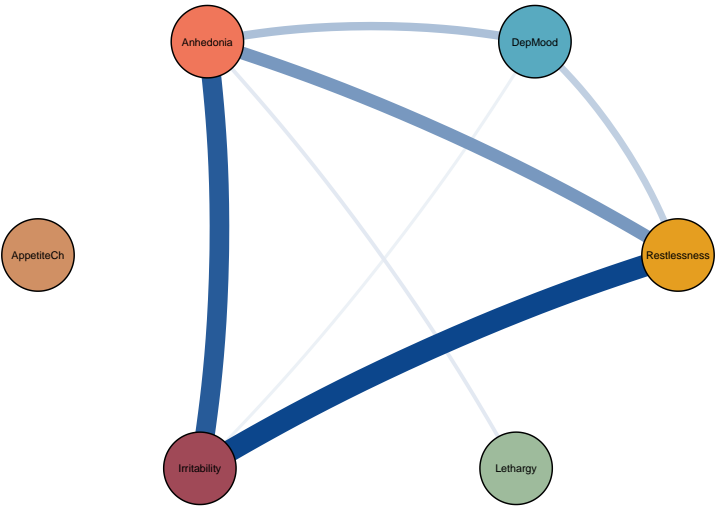


Symptom dynamics of MDD patients with IDS–SR score: 45

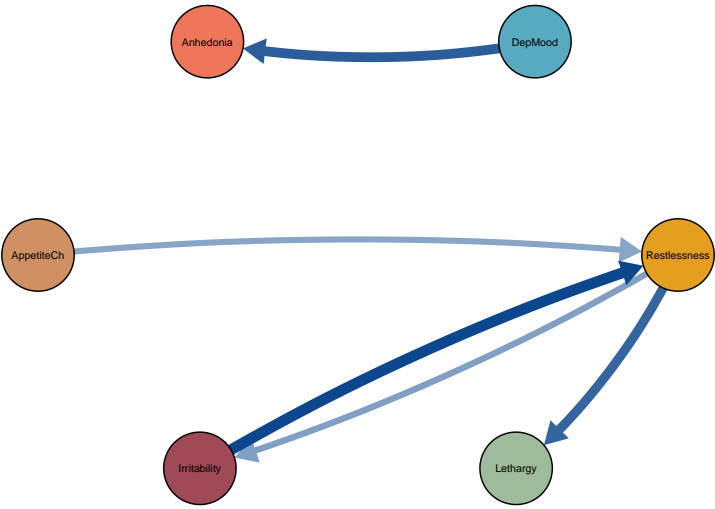
Patient 63: Temporal



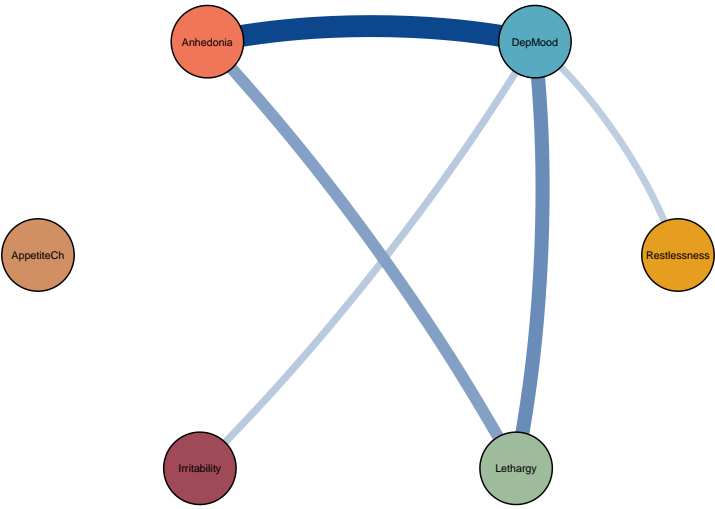
Patient 63: Contemporaneous



Patient 64: Temporal

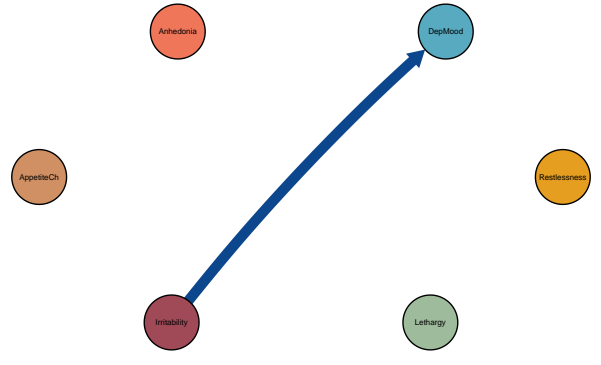


Patient 64: Contemporaneous

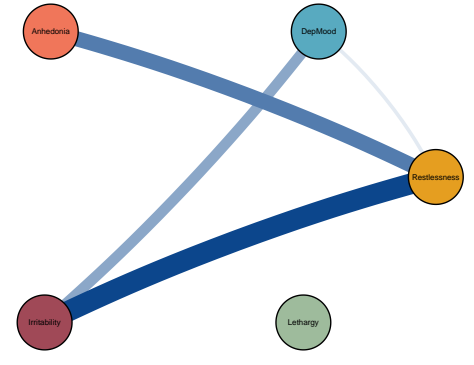


Symptom dynamics of MDD patients with IDS-SR score: 46

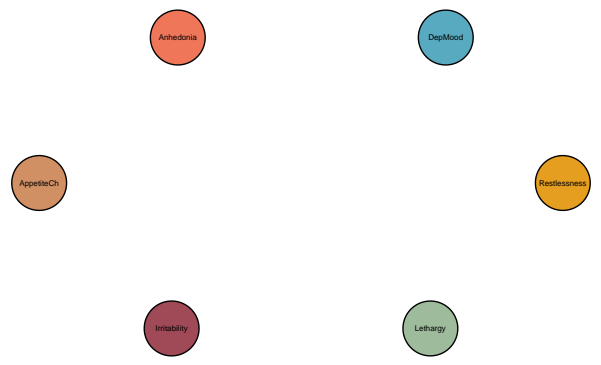Patient 65: Temporal



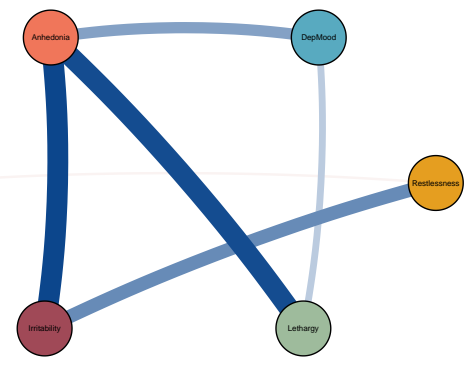
Patient 65: Contemporaneous



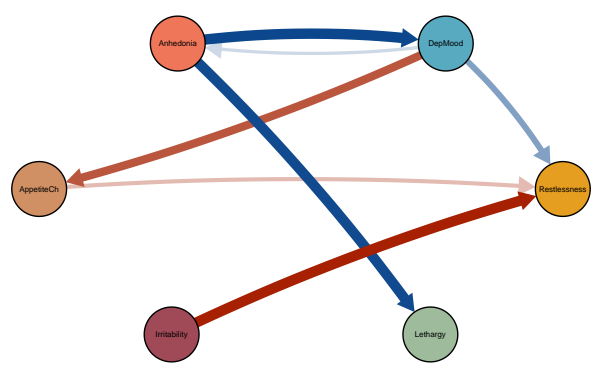
Patient 66: Temporal



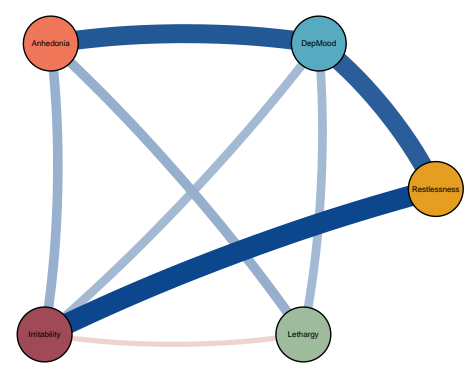
Patient 66: Contemporaneous



Patient 67: Temporal

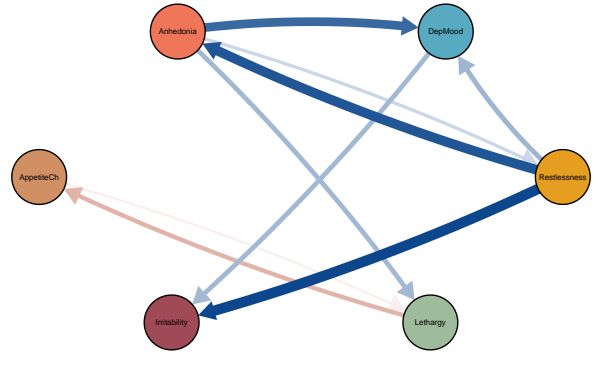


Patient 67: Contemporaneous

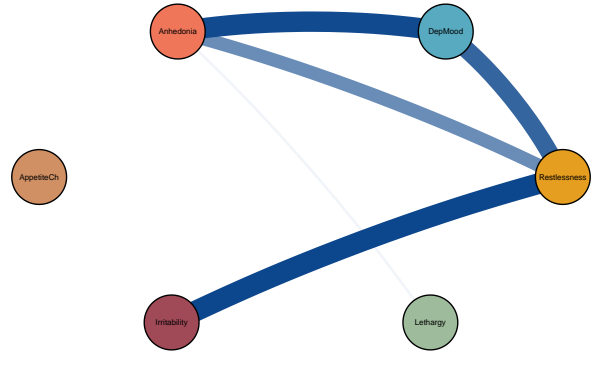


Symptom dynamics of MDD patients with IDS-SR score: 47

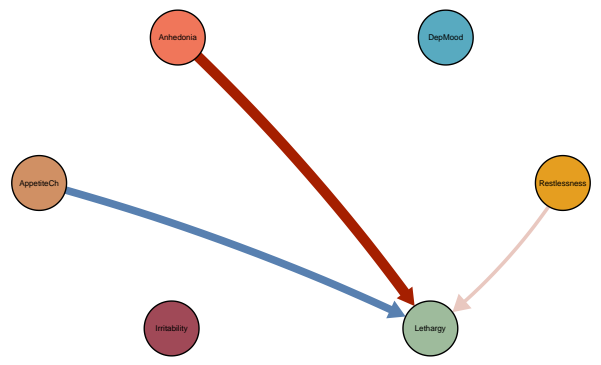
Patient 68: Temporal



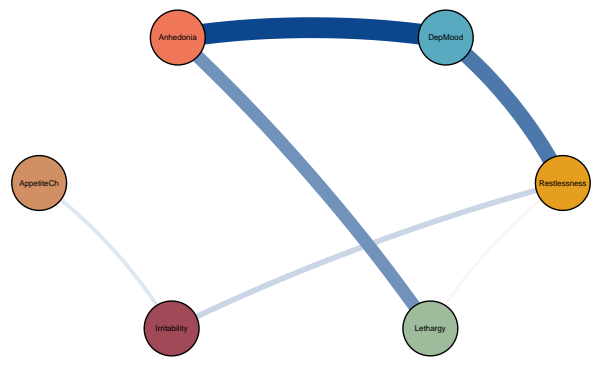
Patient 68: Contemporaneous



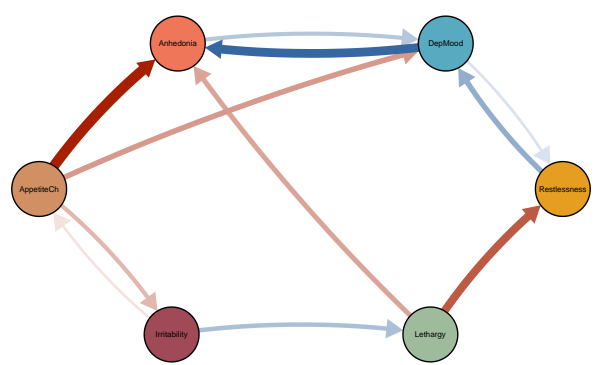
Patient 69: Temporal



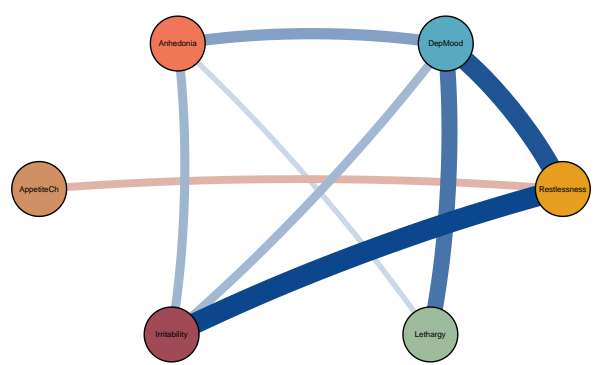
Patient 69: Contemporaneous



Patient 70: Temporal



Patient 70: Contemporaneous

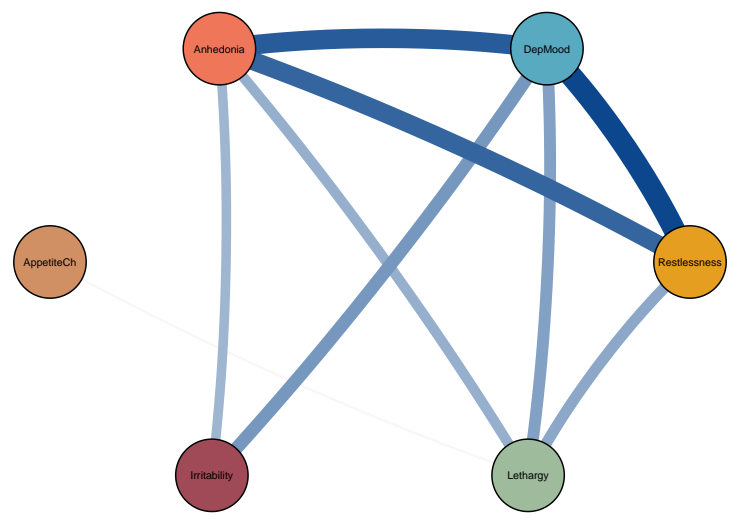


Symptom dynamics of MDD patients with IDS–SR score: 49

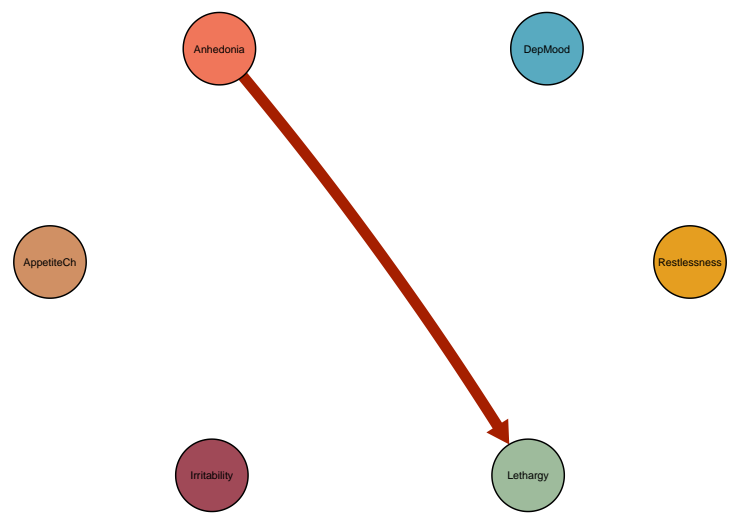
Patient 71: Temporal



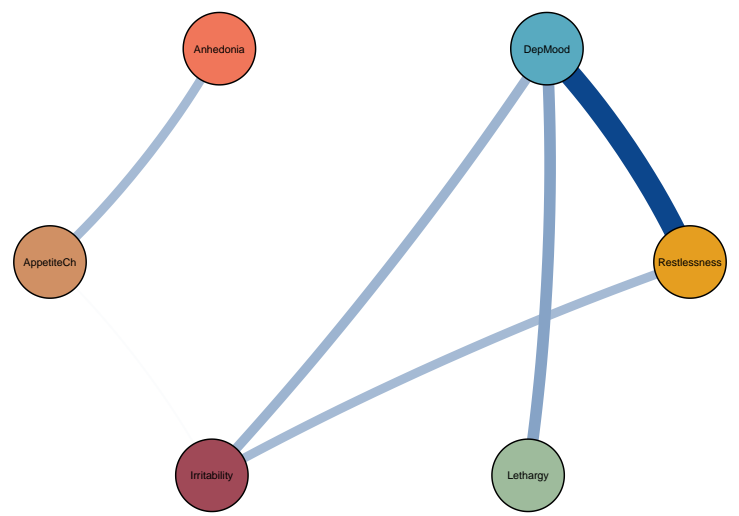
Patient 71: Contemporaneous



Patient 72: Temporal

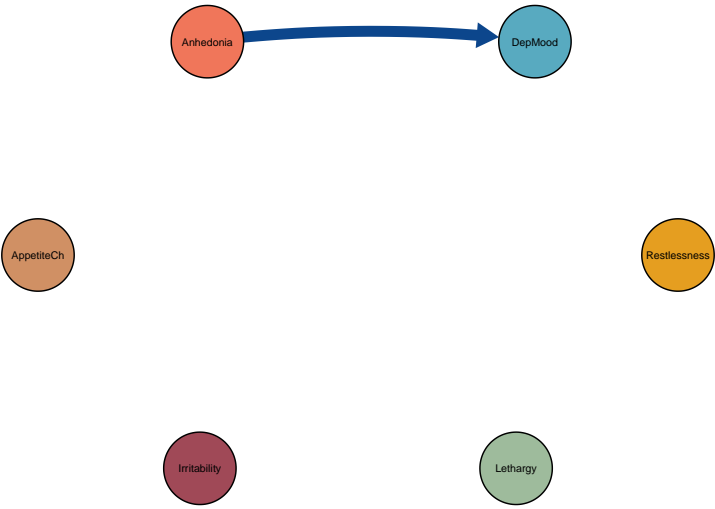


Patient 72: Contemporaneous

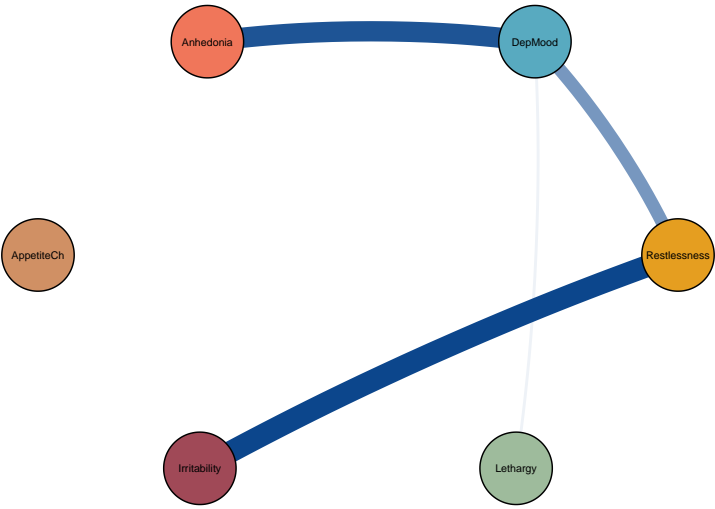


Symptom dynamics of MDD patients with IDS–SR score: 51

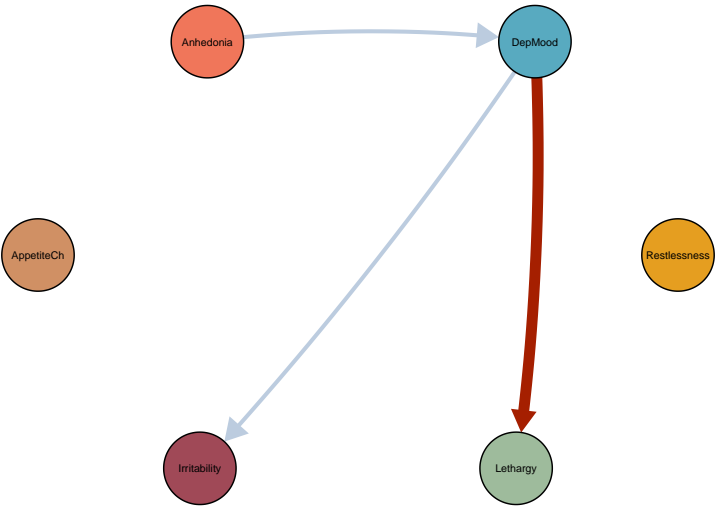Patient 73: Temporal



Patient 73: Contemporaneous



Patient 74: Temporal



Patient 74: Contemporaneous

