

occurrence of herniation and its relationship to outcome, but the benefits of deferring LP in the presence of signs of possible herniation.

Acknowledgements

We are grateful to Dr (Mrs) AN Olu-Eddo, FMCPaeth, for the autopsy report.

George O Akpede, MB BS FWACP FMCPaed
 Professor and Consultant Paediatrician
 Neurology and Infectious Diseases Unit
 Department of Paediatrics
 Otiabor Okhae Teaching Hospital
 PMB 8, Irrua
 Edo State
 Nigeria
 E-mail: public@fidelsemper.com

References

1. Akpede GO, Ambe JP. (2000) Cerebral herniation in pyogenic meningitis: prevalence and related dilemmas in emergency room populations in developing countries. *Developmental Medicine & Child Neurology* **42**: 462–9.
2. Williams CPS, Swanson AG, Chapman JT. (1964) Brain swelling with acute purulent meningitis – report of treatment with hypertonic intravenous urea. *Pediatrics* **46**: 220–7.
3. Dodge PR, Swartz MN. (1965) Bacterial meningitis: a review of selected aspects. II: Special neurologic problems, postmeningitic complications and clinicopathological correlations. *New England Journal of Medicine* **272**: 954–60, 1003–10.
4. Quagliarello V, Scheld WM. (1992) Bacterial meningitis: pathogenesis, pathophysiology, and progress. *New England Journal of Medicine* **327**: 864–72.
5. Phillips RE, Solomon T. (1990) Cerebral malaria in children. *Lancet* **336**: 1355–60.
6. Rennick G, Shann F, Campo J. (1993) Cerebral herniation during bacterial meningitis in children. *British Medical Journal* **306**: 953–5.
7. Anonymous. (1979) Intracranial pressure in childhood convulsions. *Lancet* **i**: 139–40.
8. Mellor DH. (1992) The place of computed tomography and lumbar puncture in suspected bacterial meningitis. *Archives of Disease in Childhood* **67**: 1417–9.
9. Akpede GO, Akuhwa RT, Ogiiji EO, Ambe JP. (1999) Risk factors for an adverse outcome in bacterial meningitis in the tropics: a reappraisal with focus on the significance and risk of seizures. *Annals of Tropical Paediatrics* **19**: 151–9.
10. White NJ, Phillips Re, Looareesuwan S, Chanthavanich P, Warrel DA. (1988) Single dose phenobarbitone prevents convulsions in cerebral malaria. *Lancet* **ii**: 64–6.
11. Herson VC, Todd JK. (1977) Prediction of morbidity in Hemophilus influenzae meningitis. *Pediatrics* **59**: 35–9.
12. Ojinnaka NC, Iloeje SO. (1998) Neurological complications of childhood bacterial meningitis as seen in Enugu. *Nigerian Journal of Paediatrics* **25**: 53–6.
13. Duffy GP. (1969) Lumbar puncture in the presence of raised intracranial pressure. *British Medical Journal* **i**: 407–9.

Erratum

'Brain dysmorphology in Individuals with Severe Prenatal Alcohol Exposure'

Archibald et al.
 DMCN **43**: 148–54.

The published version of Figure 2f on page 151 of the March issue of DMCN was incorrectly labelled. We apologise for this error. The correct figure is shown below.

Fig. 2f

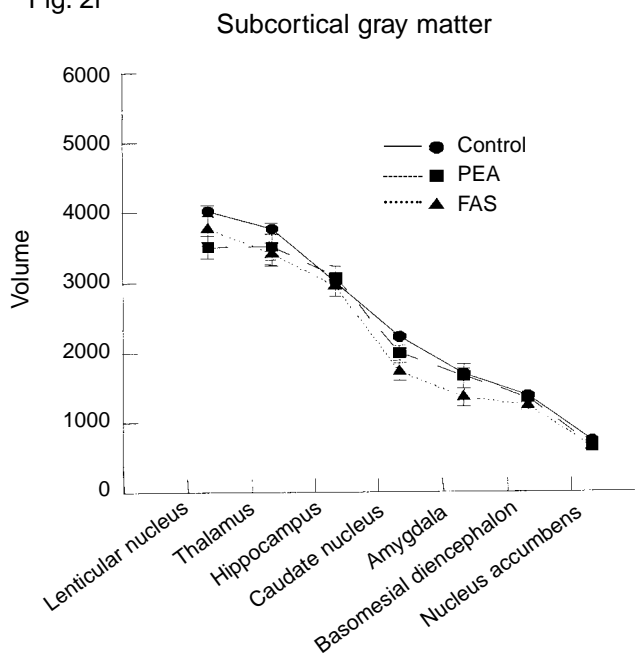


Figure 2: Mean and standard errors of raw volumes in voxels for regions or tissue types. Regions are ordered by size on x-axis and line graphs connect group means. Comparisons ... (f) of volumes of subcorical regions.